



Gallstones

Ian J. Beckingham

s0010 Introduction

p0050 The gallbladder serves as a reservoir to hold bile and release it in a bolus when fat is ingested (Fig. 11.1). Fat in the stomach results in the release of cholecystokinin (CCK) which causes contraction and emptying of the gallbladder as food enters the duodenum. Bile helps to emulsify fat within the small bowel and aid its absorption. Whilst in the gallbladder, bile is concentrated by the absorption of up to 70% of the water content.

p0055 Many animals do not have gallbladders – all members of the deer family (except the musk deer), all of the equine family, camels, giraffes, elephants, rhinoceroses, whales, some birds (such as doves, pigeons and parrots), rats and some fish, do not have gallbladders. It is thought that the presence of a gallbladder is related to the interval of food intake. Thus animals, like humans, cats and dogs, which take in food at intervals, require a larger amount of bile acids to aid digestion of fats arriving in a bolus, rather than in a more constant stream.

p0060 In some societies the gallbladder is attributed with more than just physical properties. In Korea, the flighty nature of deer is blamed on its lack of a gallbladder, and when a person acts eccentrically or irrationally Koreans say the person lacks a gallbladder. Conversely, when someone is brave, bold and daring, they say the person has a big gallbladder.¹ The Chinese proclaim the calming influence of bile and use powdered bovine gallstones in their traditional medicines as an antipyretic and to aid sleep and cure diseases of the liver and epilepsy. Ox gallstones are also used as an aphrodisiac and bovine gallstones can fetch up to \$14000 a kilo on the commercial market.

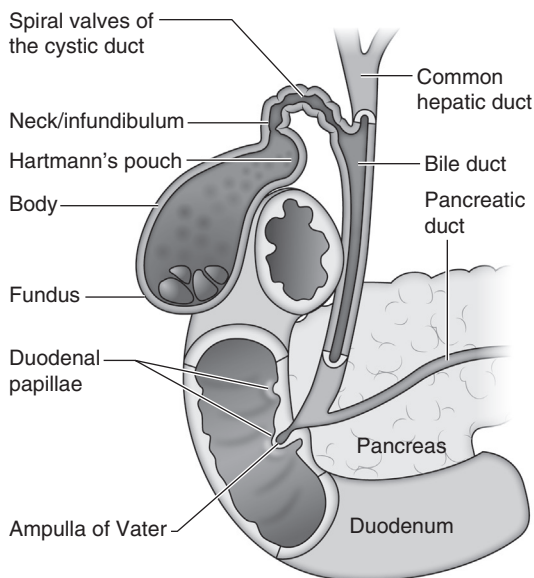
Pathogenesis of gallstones

s0015 Bile is composed of a complex solution of bilirubin (the byproduct of effete red blood cells), cholesterol, fatty acids and various minerals. If one or more of the major components is present in excess, then the solution becomes supersaturated and cholesterol crystals form within the bile (Fig. 11.2). These eventually coalesce to form cholesterol or ‘mixed’ (cholesterol/bilirubin) gallstones. Cholesterol supersaturation can result from either excessive hepatic secretion of cholesterol, or decreased hepatic secretion of bile salts or phospholipids with relatively normal cholesterol secretion. In >90% of patients, supersaturation results from altered hepatic cholesterol metabolism.^{2,3} For stones to form there is a need for a nidus, and mucin that is secreted by the gallbladder wall may serve as a nidus and act as a pro-nucleating (crystallisation-promoting) protein. Variations in mucin composition and decreased degradation of mucin by lysosomal enzymes are associated with a higher incidence of stone formation.⁴

Loss of gallbladder motility and excessive sphincteric contraction are also associated with gallstone formation (Fig. 11.3). Hypomotility leads to prolonged bile stasis (delayed gallbladder emptying) and decreased reservoir function. If the situation persists for long enough, crystals coalesce with formation of biliary sludge and subsequently stones.⁵

p0075 Patients with Crohn’s disease, or who have undergone intestinal resection or total colectomy, are also more prone to develop cholesterol stones. This is due to impaired enterohepatic circulation leading to reduced hepatic secretion of bile salts in the bile (Fig. 11.4). This results in higher concentration

Chapter 11



f0010 **Figure 11.1** • Anatomy of the gallbladder and bile ducts.

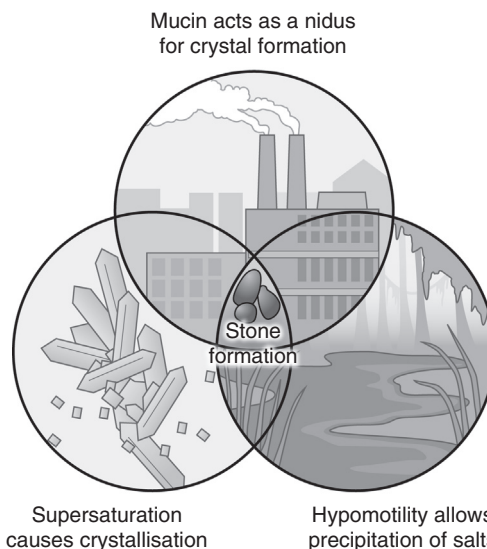
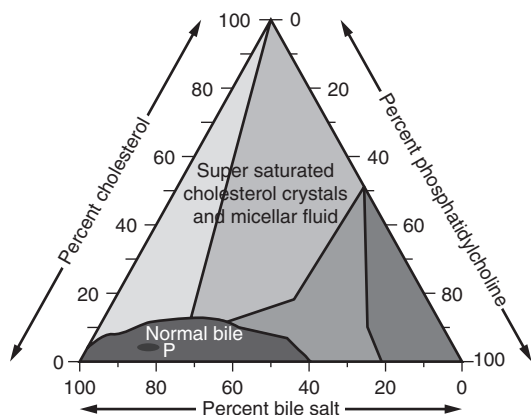


Figure 11.3 • Components required for gallstone formation. f0020



f0015 **Figure 11.2** • Triangular coordinate equilibrium phase diagram of the cholesterol-phospholipid-bile salt system in the gallbladder. Bile composition at point P (normal, non-lithogenic bile); bile salts (80%); phospholipids acids (15%); cholesterol 5%.

and decreased solubilisation of cholesterol and its precipitation as crystals, with eventual stone formation.

s0020 **Risk factors**

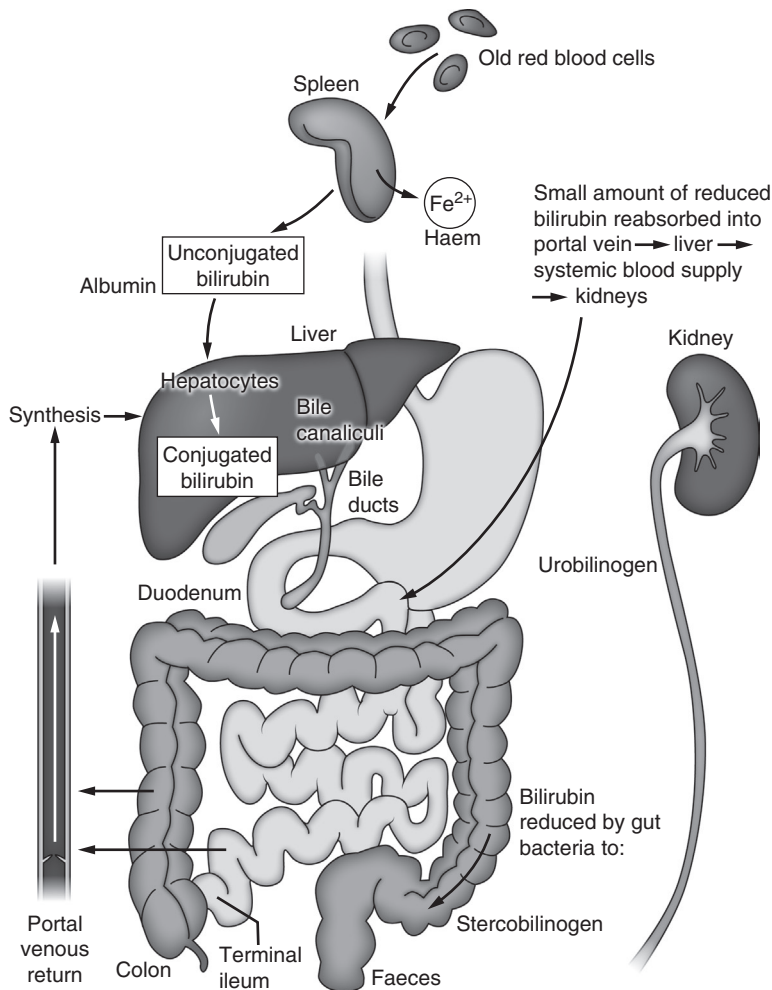
p0080 As with most diseases, the development of gallstones is caused by a mixture of genetic and environmental factors. Patients with cholelithiasis often have a strong family history, with gallstones occurring three times more frequently in first-degree relatives than in spouses or unrelated controls.⁶ It has been estimated that genetic factors account for

approximately 25% of gallstones.⁷ Gallstones are most common in white European and American populations and least common in black Africans (Fig. 11.5). Intermediate rates are found in Asian populations. The highest prevalence is seen in native American populations with a prevalence of 60% in the Pima Indian population of Southern Arizona.

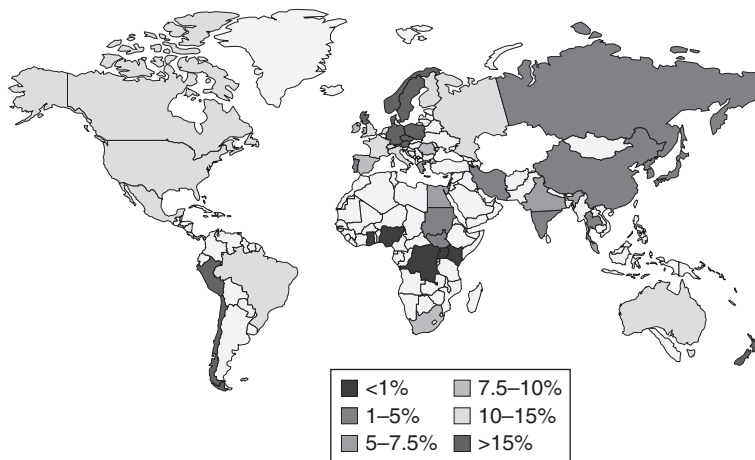
Female gender (10:1 female to male ratio), previous pregnancy and a family history of gallstone disease are highly correlated with cholelithiasis (Box 11.1).⁸ Oestrogen increases cholesterol secretion and diminishes bile salt secretion, increasing the cholesterol saturation within bile. Diminished gallbladder motility is commonly seen during pregnancy, with a 10–15 times higher incidence of cholelithiasis seen in women who have had children.⁸ Biliary sludge is found in 5–30% of pregnant women and definitive gallstones become established in 5%.⁹

A number of disease processes can result in the supersaturation of cholesterol in bile, including rapid weight loss in the morbidly obese patient (due to excess cholesterol within the bile), total parenteral nutrition (which induces gallbladder hypomotility in the presence of high lipid levels), and drugs that promote cholesterol secretion into the bile, e.g. fibrates.

Other risk factors include a high dietary intake of fats and carbohydrates, a sedentary lifestyle, type 2 diabetes mellitus and dyslipidaemia (increased triglycerides and low HDL). A diet high in fats and carbohydrates predisposes a patient to obesity, which increases cholesterol synthesis, biliary secretion of cholesterol, and cholesterol supersaturation. Patients with a BMI >45 have a 7-fold higher incidence of gallstones compared with non-obese women.¹⁰



f0025 **Figure 11.4** • Enterohepatic bile circulation.



f0030 **Figure 11.5** • Geographical prevalence of gallstones. Adapted from Figge A, Matern S, Lammert F. Molecular genetics of cholesterol cholelithiasis: identification of human and murine gallstone genes. *Z Gastroenterol* 2002;40(6):425–32.

Chapter 11

b0010 **Box 11.1** • Risk factors mnemonic

- u0010 • Female
 - u0015 • Fair (Caucasian)
 - u0020 • Fat (high cholesterol excretors, rapid weight loss, obesity)
 - u0025 • Fertile (post pregnancy and gallbladder stasis)
 - u0030 • Forties (requires several years to develop from crystals to stones)
- p0040 The old adage acts as a good mnemonic and still holds more than a modicum of truth.

However, a direct correlation between high dietary intake of fats and cholelithiasis risk has not been directly established.

s0025 **Pigment stones**

p0100 Black pigment stones account for approximately 10% of gallstones. They are formed when there is an excess of unconjugated bile as a result of increased enterohepatic circulation of bilirubin caused by excessive breakdown of red blood cells. The increased bilirubin concentration within the bile results in precipitation of calcium bilirubinate to form black pigmented stones. These stones are most frequently seen in patients with chronic haemolytic anaemias (e.g. hereditary spherocytosis, sickle cell disease, B thalassaemia), ineffective erythropoiesis (e.g. pernicious anaemia) and liver cirrhosis.

p0105 Patients with ileal disease (e.g. Crohn’s disease), total colectomy or extended ileal resections have impairment of intestinal bile salt absorption and an increased incidence of gallstones. These may be cholesterol stones due to loss of specific bile salt transporters in the terminal ileum resulting in excessive bile salt excretion in faeces and a diminished bile salt pool. However, in some patients these changes may also lead to formation of pigment gallstones because increased bile salt delivery to the colon enhances solubilisation of unconjugated bilirubin, thereby increasing bilirubin concentrations in bile (Fig. 11.4). Patients with cystic fibrosis also have bile acid malabsorption and approximately 20–30% of patients will develop gallstones.

p0110 Brown pigment stones differ from other types of gallstone in that they predominate within the other areas of the biliary tract, particularly the intrahepatic ducts, as well as within the gallbladder. They are mostly seen in South-East Asia and are usually associated with parasite infestation and *Escherichia coli* infection (see later section – Intrahepatic stone disease).

s0030 **Presentation**

p0115 Gallstones are very common, with an incidence of 10–15% of the adult population.¹¹ The majority of people with gallstones are asymptomatic and

therefore unaware of their presence. In post-mortem studies, approximately 90% of people with gallstones had no attributable symptoms during their lifetime.

Biliary pain

s0035

Gallstones cause symptoms when the cystic duct p0120 is occluded during the attempted expulsion of bile from the gallbladder. The resulting contraction of the gallbladder smooth muscle results in activation of visceral nerve fibres in the gallbladder wall and the sensation of referred pain in the associated dermatome (T9) in the epigastrium and radiation round or through to the back. Viscerally innervated pain is often poorly localised and may be accompanied by nausea or vomiting. Local cytokine release can cause irritation of the adjacent parietal peritoneum resulting in pain in the right upper quadrant. The pain lasts for a significant period of time (typically 30 minutes to several hours) and may be related in part to ischaemia within the gallbladder wall as a result of muscular occlusion of the gallbladder microcirculation. The severity of the pain is sufficient to interfere with performance of daily activities. It is frequently very severe and often described by women as ‘worse than childbirth’. The popular term ‘biliary colic’ is a misnomer since the pain is constant and unrelenting and not colicky in nature. It is therefore more accurately referred to as biliary pain. Similarly, use of the term ‘chronic cholecystitis’ should be avoided since it implies the presence of a chronic inflammatory infiltrate that may or may not be present. The number of stones, their size and the thickness of the gallbladder wall do not correlate well with the presence or absence, or severity of biliary symptoms. In many patients with significant biliary pain the gallbladder looks quite normal at the time of surgery.

The importance of clarifying what constitutes p0125 true biliary pain is to better predict relief following surgery (Table 11.1).¹² Cholecystectomy fails to relieve ‘biliary pain’ in 10–30% of patients with documented gallstones.^{13,14} It is observed that patients who have had cholecystectomy for biliary pain often have improvement in other symptoms,

Table 11.1 • Typical features of biliary pain

t0010

Location	Epigastric/right upper quadrant
Duration	>30 minutes
Radiation	Round or through to back (band-like)
Severity	Severe (inhibits daily activity)
Periodicity	Intermittent
Less strongly associated	Nocturnal onset Post fatty meal

such as belching and low-grade epigastric discomfort ('biliary dyspepsia'). Some patients may be offered surgery for these symptoms alone. However, these more vague symptoms are probably vagal nerve-mediated and also frequently associated with other functional gut disorders such as irritable bowel syndrome or gastro-oesophageal reflux disease. Thus, results for cholecystectomy in patients with 'biliary dyspepsia' alone have worse outcomes than in patients who have more classic bouts of acute biliary pain, and should only be undertaken after appropriate exclusion of other causes where possible and with clear counselling that benefits are less likely.

p0130 Once patients have started to develop symptoms from their gallstones their likelihood of having further episodes is approximately 38–50% per annum.^{15,16} Overall, approximately 30% of patients will never have further symptoms. The risk of developing complications of gallstones is higher in patients with symptomatic gallstones than in asymptomatic patients and is approximately 1–2% per annum.¹⁷

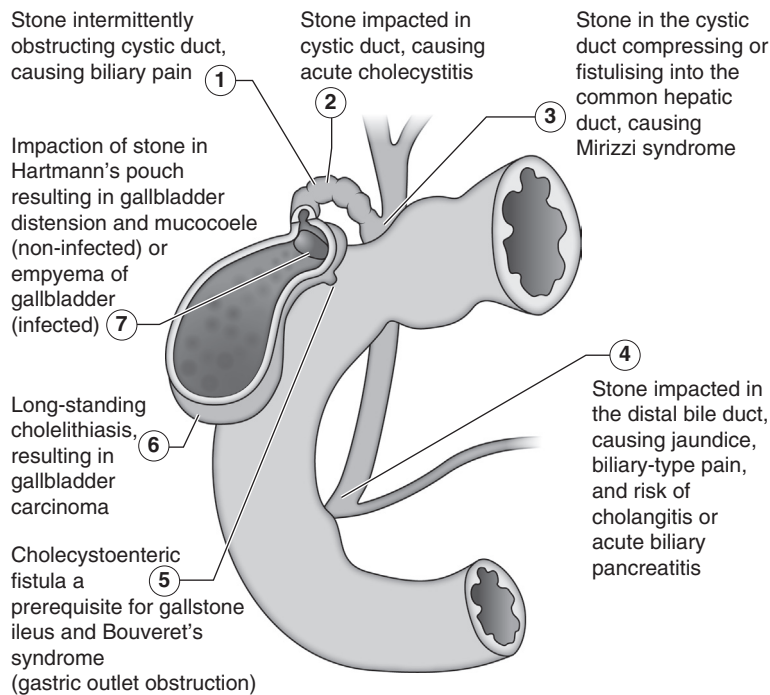
s0040 **Acute cholecystitis**

p0135 When biliary pain persists for more than a few hours and is accompanied by localised right upper quadrant (RUQ) discomfort, it is termed acute cholecystitis.

Pathophysiologically, prolonged obstruction of the cystic duct causes release of prostaglandins within the gallbladder mucosa resulting in fluid secretion producing a cycle of increased distension and further mucosal damage and inflammation. The inflammatory process results in irritation of the parietal peritoneum. Palpation of the RUQ is tender, and inspiration with the examiner's hand in this region results in pain as the inflamed gallbladder pushes against it (Murphy's sign), which can similarly be confirmed with the ultrasound probe. Inflammatory markers (WCC/ESR/CRP) may be elevated. Liver function tests are often deranged as a result of localised inflammation within the adjacent liver parenchyma or due to compression of the common bile duct from the inflamed gallbladder. Secondary infection can develop in this setting but is rarely the primary event.

The condition may, however, evolve and can result p0140 in a variety of complications (Fig. 11.6):

- Obstruction of the cystic duct, usually by a large u0035 stone in Hartmann's pouch, can cause a tense tender gallbladder due to mucus (mucocoele).
- If the obstructed gallbladder becomes infected, u0040 it may fill with pus (empyema), presenting classically with high swinging fevers, rising white cell count and a significantly elevated C-reactive protein (>50).



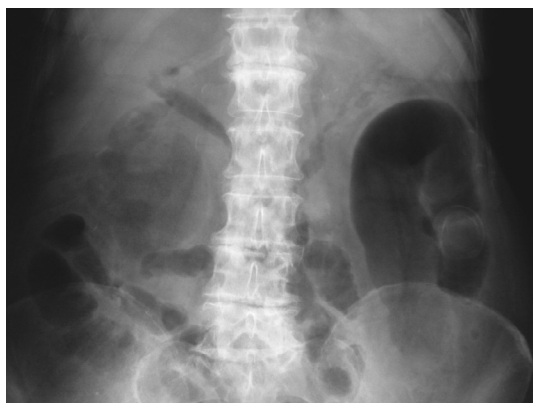f0035 **Figure 11.6** • Potential complications of gallstones.

Chapter 11

- u0045 • Emphysematous cholecystitis may develop when secondary infection in the gallbladder wall occurs with gas-forming bacteria, such as *Clostridium welchii*, *Escherichia coli* or anaerobic streptococci. Imaging may reveal the presence of gas within the gallbladder wall. It is most commonly seen in elderly diabetic men.
- u0050 • The inflamed gallbladder may become adherent to an adjacent loop of bowel (duodenum, jejunum or colon) and eventually rupture into it, discharging its contents. Rarely a large stone passes through the gallbladder wall into the small bowel and causes obstruction (gallstone ileus) (Fig. 11.7). Gastric outlet obstruction due to impaction of a gallstone in the duodenum is known as Bouveret's syndrome. Discharge into the colon only rarely causes obstruction due to the larger diameter of the colon but can be encountered at cholecystectomy as a cholecysto-colic fistula.
- u0055 • The gallbladder may rupture into the peritoneal cavity resulting in free pus and generalised peritonitis (1%), or may become walled off by adjacent bowel and omentum and form a localised pericholecystic abscess.

s0045 Common bile duct stones

- p0170 Approximately 8–16% of patients with symptomatic gallbladder stones will have simultaneous common bile duct (CBD) stones and (with the exception of brown pigment stones) the vast majority (if not all) of these stones originate from the gallbladder and pass from there through the cystic duct into the CBD. The natural history of these CBD stones is



- f0040 **Figure 11.7** • Gallstone ileus. Large stone impacted in small bowel causing obstruction. Note pneumobilia from the cholecysto-jejunal fistula.

unknown, but there is evidence that many do not cause symptoms. Faecal sampling of patients with multiple gallbladder stones confirms that stones often pass freely into the gut without symptoms. Furthermore, studies of patients with known CBD stones awaiting or having had cholecystectomy and who are then re-imaged often show passage of the stones from the CBD.^{18,19} Incidental (asymptomatic) CBD stones are also identified in patients undergoing imaging for unrelated non-biliary conditions. Thus, it would appear that many CBD stones may never cause any problems at all. However, because of the uncertainty in their natural history, once CBD stones are discovered, currently most clinicians would advise patients to have them removed, even if they are asymptomatic.

When stones enter the CBD and cause partial or complete obstruction, patients present with obstructive jaundice with an elevated bilirubin (conjugated), alkaline phosphatase (ALP) and gamma-glutamyl transferase (GGT). The transaminases (AST/ALT) may also be elevated ('a mixed pattern') as a result of secondary inflammation of the hepatocytes. Classically, obstructive jaundice is accompanied by pale stools due to lack of the brown pigment stercobilin (which requires the presence of bilirubin in the gut) and dark urine (due to increased bilirubin in the urine). These features are not always present, particularly in the early phases of obstruction or in incomplete biliary obstruction. Obstructive jaundice resulting from CBD stones is often associated with biliary pain, or with a history of biliary pain from previous attacks of gallbladder pain. This contrasts with jaundice associated with malignant obstruction which is usually painless, but the distinction is not absolute. As obstruction progresses, dilatation of the biliary tract occurs which is evident on ultrasound or cross-sectional imaging (e.g. magnetic resonance imaging [MRI], computed tomography [CT]).

CBD stones, when present, are only occasionally identified with ultrasound because the lower part of the bile duct lies behind the gas-filled duodenum preventing visualisation. The presence of a dilated CBD or intrahepatic ducts with elevated liver function tests (LFTs) raises the suspicion of CBD stones, which are best visualised by magnetic resonance cholangiopancreatography (MRCP) or endoscopic ultrasound (EUS). A recent meta-analysis has shown that EUS and MRCP are equally good at identifying CBD stones, with similar sensitivity and specificity.²⁰ However, EUS is more costly, less widely available and more invasive than MRCP. These techniques have replaced the use of endoscopic retrograde cholangiopancreatography (ERCP) (with its attendant risks) as a diagnostic tool.

If infection develops in an obstructed bile duct, jaundice is invariably accompanied by high temperatures and RUQ pain (Charcot's triad) and is

termed cholangitis. Fevers are typically fluctuating, with high temperatures of 39–40°C punctuated by chills and shaking bouts (rigors). Cholangitis is caused by secondary infection within the biliary tract, usually caused by enteric bacteria from the duodenum (most commonly Gram-negative spp. – *E. coli* (25–50%), *Klebsiella* spp. (15–20%), *Enterobacter* spp. (5–10%) or less commonly, Gram-positive bacteria, *Enterococcus* spp. (10–20%)).²¹ Early management with intravenous antibiotics (broad-spectrum cephalosporin or ciprofloxacin) followed by early decompression of the ducts by stone removal or stenting is essential. Failure to treat this condition frequently results in septicaemia, which can be fatal.

s0050 **Acute pancreatitis**

p0190 CBD stones (usually small) may pass out of the papilla at the bottom of the bile duct and in some cases result in acute pancreatitis. The most popular theory for the pathogenesis of gallstone pancreatitis is that an impacted gallstone in the distal bile duct obstructs the pancreatic duct, increasing pancreatic pressure, thereby damaging ductal and acinar cells (see Chapter 14).

s0055 **Mirizzi syndrome**

p0195 First described by Argentinian surgeon Pablo Mirizzi in 1948, the term is used to describe the situation where a stone impacted in Hartmann’s pouch produces an inflammatory process that results in adherence of Hartmann’s pouch to the CBD with loss of the space between the two structures (i.e. obliteration of Calot’s triangle). The result is a partial obstruction of the common hepatic duct (CHD) with deranged LFTs. The most useful subclassification is into type I, where there is no fistula present, and type II, where the stone has eroded into the bile duct itself resulting in a cholecysto-choledochal fistula (Fig. 11.8).

s0060 **Intrahepatic stone disease**

p0205 In certain parts of the world primary bile duct stones (synonyms include intrahepatic stone disease (IHSD), oriental hepatolithiasis, cholangiohepatitis, recurrent pyogenic cholangitis, Hong Kong disease), form by a very different pathogenesis to cholesterol and black pigment stones, and present with a different clinical picture. The greatest frequency of this disease is seen in South-East Asia where it has been associated with the liver fluke *Clonorchis sinensis*. However, it also exists in other areas of the world, most notably South Africa, Pakistan and Colombia in the absence of

Clonorchis, where the main linked epidemiological factor is severe poverty. In these communities, there may be an association with the round worm *Ascaris lumbricoides* infestation.

Stones formed in this disease are very different p0210 from cholesterol and bilirubin-rich stones and are brown, soft and friable. The stones form in any part of the biliary tract as a result of anaerobic-bacteria-secreting enzymes that hydrolyse ester and amide linkages in biliary lipids as insoluble anions or calcium salts. These precipitates deposit on obstructing elements such as small cholesterol crystals, black stones from the gallbladder, parasite eggs and dead worms or flukes.²²

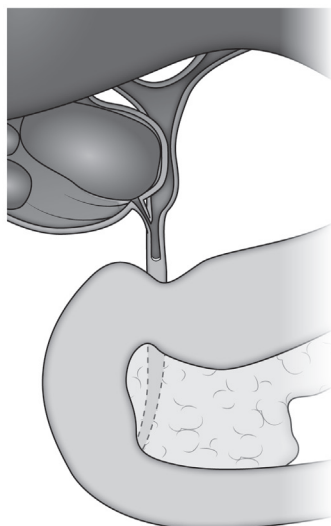
Patients with IHSD present with sepsis and RUQ p0215 pain, and initial management is with antibiotics. Symptoms are far more commonly related to ductal stones, and infective and inflammatory processes around the stones result in strictures and proximal dilatation of the ducts. Simple cases caught early can be managed by decompression of pus from the CBD with a plastic stent. Subsequent definitive surgical management aims to clear the biliary tract of stones, provide adequate biliary drainage and, where necessary, provide adequate access to the biliary duct. When there is an extrahepatic or hilar duct stricture, hepatico-jejunostomy is performed leaving the afferent loop long and fixing it to the abdominal wall as an ‘access loop’ which permits subsequent percutaneous or endoscopic management of recurrent stones and strictures.²³ A proportion of patients require resection of an atrophied portion of the liver containing multiple stones. The disease more frequently affects the left lobe than the right. Patients with intrahepatic stone disease have a 10% risk of developing cholangiocarcinoma.²⁴

Management of gallstones s0065

Conservative s0070

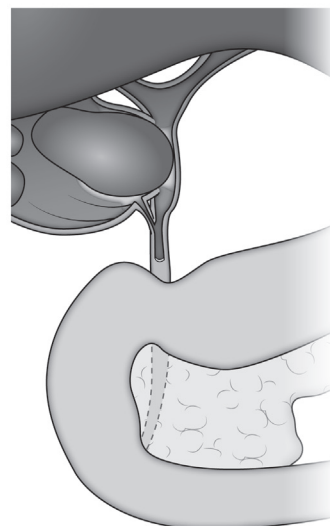
✓ Asymptomatic gallstones in the gallbladder do not require further investigation or management. Patients with symptomatic gallbladder stones should be offered laparoscopic cholecystectomy unless medically unfit for surgery. b0020 p0200

Patients with gallstones without symptoms do p0220 not require treatment. The risk of people with asymptomatic cholelithiasis developing symptoms (biliary pain) is low, averaging 2–3% per year, or approximately 10% by 5 years.²⁵ Major complications related to gallstones are very rare in asymptomatic patients.²⁶ Expectant management is therefore an appropriate choice for silent gallstones in the general population.



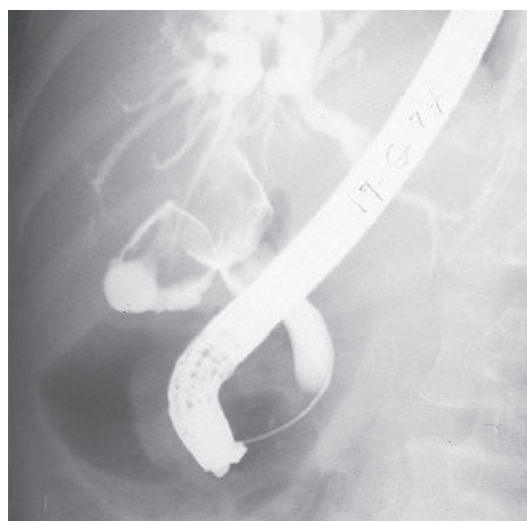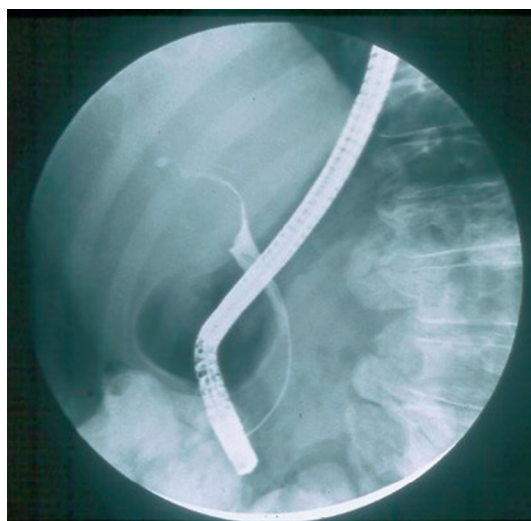
Type 1 Mirizzi
(pressure from stone in gallbladder
on common bile duct)

Type 1



Type 2 Mirizzi
(stone eroded through gallbladder
wall into common bile duct—
a cholecysto-choledochal fistula)

Type 2



f0045 **Figure 11.8** • Mirizzi syndrome.

s0075 **Non-operative management**

p0225 Even in the laboratory gallstones are difficult to dissolve and most chemicals that successfully dissolve gallstones are too toxic to ingest or inject into the gallbladder (e.g. methyl tetra butyl ether (MTBE), mono-octonoin, carbon tetrachloride). During the 1970–80s there were many attempts to develop strategies to achieve non-medical management of gallstones by oral dissolution, injection of solvents into the biliary tract and extracorporeal shock

wave lithotripsy (ESWL). However, none achieved significant reliable dissolution of the stones, even in highly selected study groups, and all required long-term bile salt therapy (with a high incidence of abdominal cramps and diarrhoea) to prevent recurrent stone formation.²⁷ With the development of laparoscopic cholecystectomy in the late 1980s with its low morbidity and ability to definitively remove the ‘stone factory’, research in this area has dwindled.

Alternative treatments such as the ‘gallbladder p0230 flush’ (essentially consisting of giving purgative

agents such as Epsom salts, olive oil and lemon juice) have been popularised by the Internet, but there is no evidence of any efficacy, although they do result in the production of small pellet-like faeces which can be mistaken by enthusiasts of the procedures as stones!²⁸

s0080 **Cholecystectomy**

p0235 Patients with biliary pain should be offered cholecystectomy as definitive treatment for their disease. Up until the early 1990s, the operation was usually performed through an incision in the right upper quadrant (Kocher's incision). The cholecystectomy procedure consists of detaching the gallbladder from the biliary tract by division of the cystic duct, division of the cystic artery and subsequent removal of the gallbladder from its attachments to the gallbladder fossa of segments 4 and 5 of the liver.

p0240 The first laparoscopic cholecystectomy (LC) was performed on 12 September 1985 by Erich Muhe in Boblingen, Germany.²⁹ Within a few years the 'open' procedure was superseded by the laparoscopic procedure, and in 2016 >98% of cholecystectomies were performed laparoscopically in England (HES data). Although never subjected to large-scale randomised trial, improved clinical outcomes led to rapid adoption. Smaller incisions result in less tissue damage, less pain and a faster recovery. The average length of stay following cholecystectomy reduced from approximately 5 days to 1 day. This has progressed further to widespread realisation that the procedure can be carried out as a day case procedure. In 2016, over 70% of laparoscopic cholecystectomies in England were performed as day case procedures (HES data). Patients are now routinely discharged within a few hours of their operation.

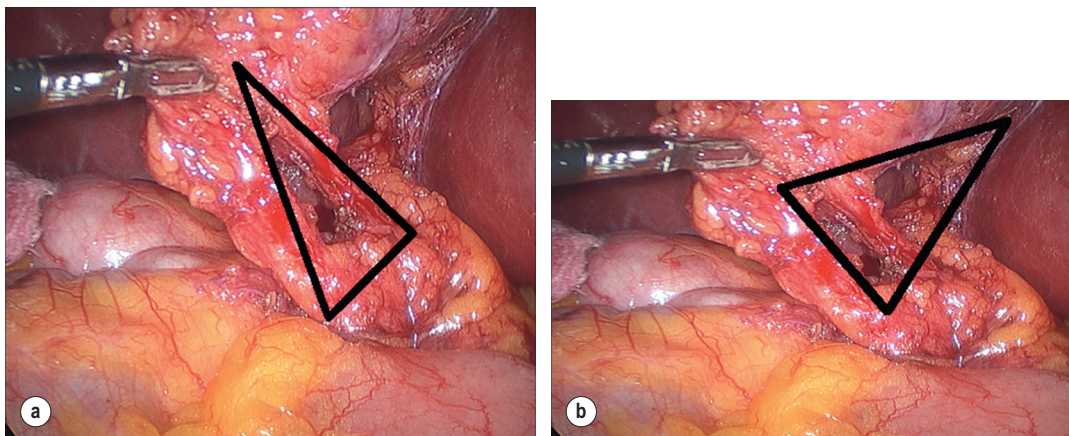
p0245 The major disadvantage following the widespread introduction of LC has been cited as a rise in the incidence of bile duct injury. The true incidence of major bile duct injury (defined as injury affecting >25% circumference of the CBD) in the open cholecystectomy era was poorly documented, but was in the order of 0.1–0.5%.^{30,31} Initial results from small series of LC demonstrated an increase in these rates,^{32,33} but subsequent large multicentre and single-centre prospective studies show that bile duct injury rates are similar to the open era at approximately 0.2–0.3%.^{34,35} A number of studies have shown that the incidence of bile duct injury is related to the surgeons inexperience with the technique,^{36,37} but the risk is always present however experienced the surgeon. When bile duct injury does occur with laparoscopic cholecystectomy, it is frequently more proximal and more extensive than

with open cholecystectomy (i.e. involving complete transection or excision of the bile duct).

The technique for a routine elective LC consists of p0250 gaining entry to the abdominal cavity under general anaesthesia, usually by an open 'Hasson' technique around the umbilical area, followed by insufflation of the cavity with carbon dioxide gas at a pressure of 12 mmHg. Following insertion classically of three additional ports in the right upper quadrant and epigastrium, the fundus of the gallbladder is grasped and pushed cephalad to expose the porta hepatis. Careful dissection of the peritoneum overlying the structures in Calot's triangle (Fig. 11.9) permits identification of the cystic artery and duct. Once clearly confirmed as such, these two structures are clipped and divided and the gallbladder is dissected free from its attachments to the undersurface of the liver. Following inspection of the gallbladder fossa to ensure no bleeding or bile leak, and that the clips on the cystic duct and artery remain intact, the gallbladder is removed, usually within a bag to reduce contamination of the port sites. The gas is emptied from the abdominal cavity and the port sites are closed. Antibiotics are not routinely given. The patient is fed within a few hours of the procedure and typically is discharged home the same day with an expectation of return to full normal function and activities over the following 2–4 weeks.

There are variations in the number and size of the p0255 ports (5 mm/12 mm) used to perform the laparoscopic procedure. Newer even less invasive techniques have been developed – SILS (Single Incision Laparoscopic Surgery) involves a single larger incision at the umbilicus to further reduce scarring;³⁸ NOTES (Natural Orifice Transluminal Endoscopic Surgery) allows scarless abdominal surgery using a flexible endoscope inserted via the mouth or vagina to remove the gallbladder.³⁹ Whilst feasibly possible, these techniques have failed to convince the majority of surgeons and patients that the elimination of three or four small incisions offers a significant benefit to patient recovery sufficient to justify the longer operative times, greater costs, greater technical challenges in more difficult cases, and increased additional potentially serious risks of these procedures. The standard four-port laparoscopic technique remains the gold standard allowing, as it does, better triangulation of Calot's triangle and reducing the potential error of excessive cephalad traction and misidentification of the CBD for the cystic duct.

There are very few true contraindications to the p0260 laparoscopic approach and most of the former contraindications, including acute cholecystitis, obesity, respiratory disease and pregnancy (middle trimester ideally when necessary), are now the preferred options compared to 'open' surgery. Multiple previous laparotomies and RUQ stomas remain a relative indication for open surgery.



f0050 **Figure 11.9** • Calot's triangle and the cystohepatic triangle. Calot's original description bounded by the cystic duct, cystic artery and common hepatic duct. (a) The cystohepatic triangle bounded by the gallbladder wall, cystic duct and common hepatic duct, with the cystic artery lying within the space. (b) Although technically incorrect, the term Calot's triangle is widely used in surgical texts to refer to the cystohepatic triangle.

p0265 b0025

✔✔ Laparoscopic cholecystectomy is the only recommended treatment for symptomatic gallbladder stones.

s0085

Intraoperative bile duct imaging and prevention of bile duct injury

p0270

Intraoperative cholangiography (IOC) is an essential skill for all surgeons performing cholecystectomy. It enables identification of CBD stones and the biliary tract anatomy. Routine use of IOC is held by some as reducing the incidence of bile duct injury;⁴⁰ however, there are many series that have shown no difference in incidence, nor in the number of bile duct injuries missed during surgery.⁴¹ Other series have shown that more than 50% of injuries revealed on the cholangiograms were missed by the operating surgeon. In the UK, selective cholangiography appears to be the favoured approach, with IOC performed in <10% of LCs (HES data).

p0275

Laparoscopic ultrasound (LUS) is a fast and reliable technique to identify CBD stones and with the addition of colour Doppler can aid identification of anatomical structures (vessels and ducts) within the porta hepatis. It is not widely available but has been shown to be superior to IOC in identification of CBD stones.⁴²

p0280

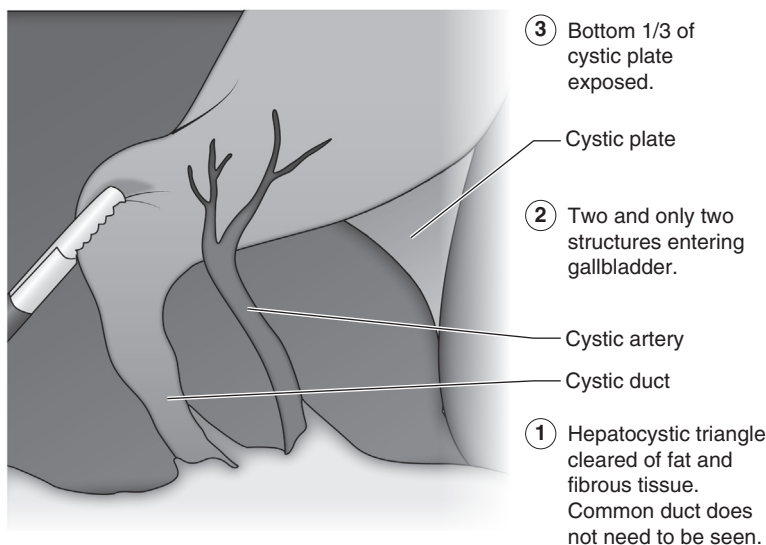
Recently indocyanine green (ICG) given intravenously 15 minutes before surgery has been shown to facilitate identification of the biliary anatomy in LC. ICG is concentrated in the liver and excreted from the biliary tract and with the aid of a near infrared (NIR) filter on the laparoscope, the ICG within the ducts fluoresces and can be clearly seen. The sensitivity of ICG in the recognition of the

cystic duct and CBD was 100% irrespective of the presence of fat or inflammation in Calot's triangle.⁴³ It has also been shown to be useful in identifying the origin of bile leaks at surgery although the specialist equipment required is not widely available at present.

Safe cholecystectomy and prevention of bile duct p0285 injuries require clear visualisation of the anatomy which itself demands proper exposure of the critical structures. Avoiding these injuries requires use of caudal and lateral traction on Hartmann's pouch to counter-tract the cephalad retraction of the fundus, and always dissecting as close to the gallbladder wall as possible. No structure should be clipped or divided unless its identity is certain and an intraoperative cholangiogram should be performed if any uncertainty exists. Conversion to open surgery should not be seen as a failure and should be considered if doubts persist.

Several methods have been proposed to reduce the p0290 incidence of bile duct injury – e.g. identification of Rouviere's sulcus, the flag technique, the infundibular technique and the critical view of safety (CVS). The critical view (Fig. 11.10) has become the most widely used technique and is the method recommended and taught by SAGES (Society of American Gastroenterological and Endoscopic Surgeons). The CVS requires demonstration of three criteria – Calot's triangle is cleared of fat and fibrous tissue; the lower third of the gallbladder is separated from the liver to expose the cystic plate; demonstration of two (and only two) structures to be seen entering the gallbladder.⁴⁴ Its usage has been shown to reduce the incidence of bile duct injury in several large studies.^{45,46}

When the anatomy in Calot's triangle is unclear p0295 as a result of inflammation and fibrosis, subtotal cholecystectomy is a safe technique avoiding the need to dissect in the hostile area of Calot's



f0055 **Figure 11.10** • The critical view of safety.

triangle. Subtotal cholecystectomy is with division of the gallbladder at the level of Hartmann’s pouch, removal of the stone(s) with or without complete removal of the posterior wall of the gallbladder and securing Hartmann’s pouch with endoloop, suture or stapler as appropriate. Occasionally the cystic duct cannot be secured at all due to friable tissues and a drain can be left, with the majority of leaks settling without further intervention. Further surgery is rarely required following subtotal cholecystectomy as long as all the stones are removed at the original procedure. In a review of over 1000 cases following subtotal cholecystectomy, further surgery was required in <2% of cases.⁴⁷ If the whole area is ‘frozen’ with dense adhesions, cholecystostomy (insertion of a drain directly into the gallbladder) offers a safe alternative allowing transfer to a specialist unit if required.

p0300 It is widely held that the majority of bile duct injuries are preventable and result from inadequate training, poor surgical technique or misidentification of the normal anatomy (Box 11.2). Perhaps surprisingly, unusual amounts of bleeding, severe inflammation and emergency operations are typically involved in <25% of injuries,⁴⁸ and it is noteworthy that in this extensive Swedish review, the patients most at risk of bile duct injury were young, slim females who had

b0015 **Box 11.2** • Bile duct injuries – risk factors

t0020	Dangerous anatomy	7%
	Dangerous pathology	9%
p0045	Dangerous surgery	84%

Adapted from Johnson GW. Iatrogenic bile duct injury: an avoidable surgical hazard. *Br J Surg* 1986;73:246–7.

not undergone previous surgery. Similar studies have suggested that 84% of injuries were in non-complicated LCs and 97% were due to perceptual errors.⁴⁹

Acute cholecystitis

s0090

Patients with acute cholecystitis generally require p0305 admission for analgesia and intravenous fluid rehydration. Non-steroidal anti-inflammatory agents such as diclofenac or indomethacin have been shown to reduce inflammation and speed recovery.⁵⁰ Broad-spectrum antibiotics, such as a second-generation cephalosporin, are recommended to prevent secondary bacterial infection.

The approach to the management of acute p0310 cholecystitis has changed radically over the last 20 years. Optimal management has shifted from leaving the cholecystectomy for 6 weeks in an effort to reduce inflammation and facilitate easier dissection following a realisation that this practice resulted in a 20% need for urgent surgery, 20% readmission rates, as well as prolonged and unnecessary pain, discomfort and inactivity. It is now recognised that surgery should ideally be undertaken within 48 hours of the onset of symptoms when the inflammatory process is still acute and before the development of more difficult fibrosis sets in. Benefits are still evident up to 10 days from onset of symptoms.^{51,52} These cholecystectomy procedures can be challenging and there remains a significant conversion to open surgery (10–30%). Surgeons operating on this group of patients must have the full repertoire of techniques and equipment (e.g. cholangiography and choledochoscopy) and be prepared to perform a subtotal cholecystectomy or cholecystostomy.

p0315 b0030

✔✔ Patients with acute presentation of cholecystitis or gallstone pancreatitis should undergo early cholecystectomy, preferably on the same admission unless there are contraindications to surgery.

heart transplant (higher incidence of post-transplant gallbladder problems) – however, the evidence in all these groups seems to suggest that complications of gallstones are not sufficiently frequent to warrant prophylactic cholecystectomy and that patients can be safely managed if symptoms develop.

s0095

Prophylactic cholecystectomy

p0320

There have been arguments made for certain patient groups to undergo prophylactic cholecystectomy – patients with diabetes mellitus (falsely assumed to have a higher incidence of acute cholecystitis and infective gallbladder complications); patients undergoing weight loss surgery (high incidence of postoperative gallstones); patients with hereditary spherocytosis undergoing splenectomy for their disease (high incidence of black pigment stones); patients awaiting

Bile duct stones

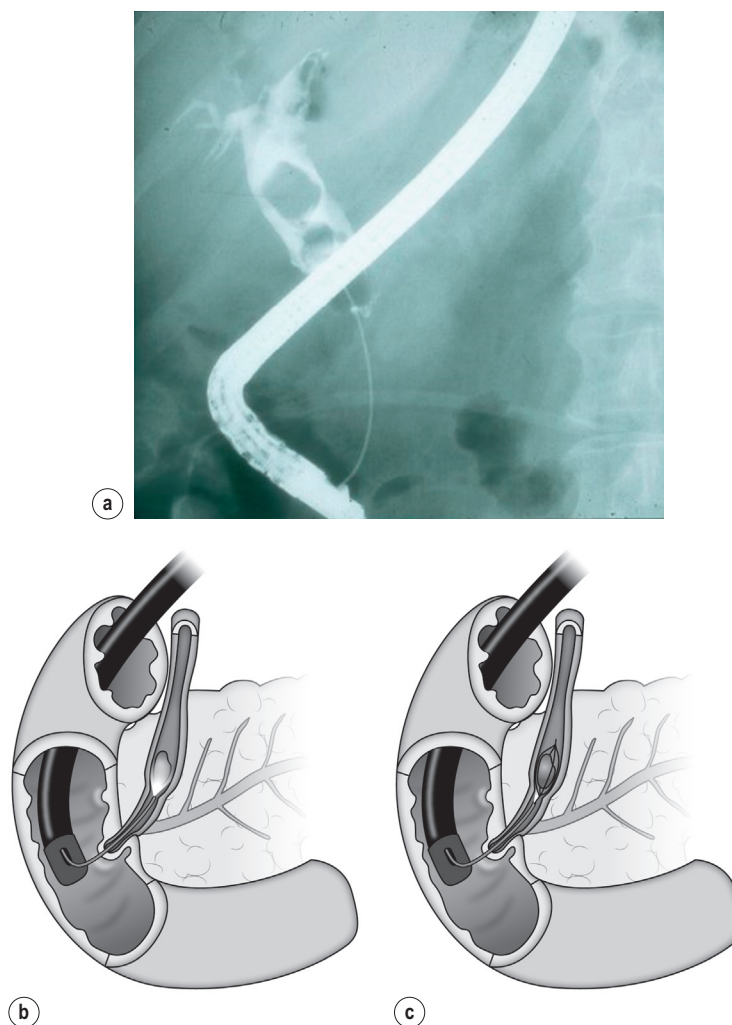
s0100

There are two main approaches to the removal of CBD stones – endoscopic retrograde cholangiopancreatography (ERCP) or surgical bile duct exploration.

ERCP

s0105

The most common approach to the management of CBD stones is by ERCP (Fig. 11.11). This procedure involves insertion of a side-viewing endoscope



f0060

Figure 11.11 • ERCP techniques for CBD stone removal: (a) balloon extraction; (b) SpyGlass cholangioscopy with contact lithotripsy; (c) basket removal.

(a duodenoscope) through the mouth into the duodenum. The papilla is cannulated with a fine cannula to enter the bile duct. The papilla can be cut using a sphincterotome, which uses diathermy to divide the sphincter of Oddi, and stones can be extracted with baskets or balloons. Larger stones can be crushed with a mechanical lithotripter. Large, impacted or multiple stones that cannot be removed can be managed by insertion of a plastic stent left within the bile duct to prevent the stone obstructing. These stones might be suitable for extraction using an ultrathin endoscope that passes down the working channel of the duodenoscope (e.g. SpyGlass endoscope). This ultrathin scope can pass up the CBD and enables direct visualisation of the stone to permit piezoelectric or laser contact lithotripsy. ERCP is performed under sedation and carries a risk of acute pancreatitis due to manipulation of the papilla (approximately 5%), bleeding or perforation (approximately 1%) and death (0.1%).

of manipulation of the duct, Dormia basket and balloon extraction with a 5-mm flexible choledochoscope. Large and impacted stones can be removed by shattering under direct vision with a piezoelectric or laser lithotripsy. Most bile ducts are primarily closed with an absorbable suture. Bile can leak through the choledochotomy suture line and a drain is usually left for 24 hours or so post procedure. Where the duct is inflamed and friable (e.g. after recent cholangitis), in the presence of pus or multiple small stones a T-tube can be left within the choledochotomy to be removed after a period of at least 2 weeks, to permit safe drainage and reduce the risk of peritoneal bile leakage. Post-procedural acute pancreatitis is rare unless there has been traumatisation of the papilla.⁵³ Regardless of exact technique, the high rates of duct clearance reported with LBDE^{54,55} can be increased to near 100% with the availability of intraductal lithotripsy.⁵⁶ Long-term results also appear favourable.^{57,58}

s0110 **Surgical bile duct exploration**

p0335 Bile duct exploration was originally performed via laparotomy but increasingly the procedure is performed laparoscopically. At open surgery, the bile duct is opened longitudinally in the mid part of the anterior wall (choledochotomy) and stones are removed with Des Jardin's forceps, flushing and the use of a flexible choledochoscope. Prior to the development of flexible choledochoscopes, retention of CBD stones was high (10–15%) and a T-tube was inserted into the choledochotomy to prevent inadvertent leakage, potential stone impaction or swelling due to the traumatic stone extraction. With optical magnification, direct visualisation and more delicate instrumentation, trauma to the bile duct was reduced, missed CBD stones were rarer and primary duct closure became more common.

p0340 Laparoscopic bile duct exploration (LBDE) can be performed either via the cystic duct (transcystic) or directly through a choledochotomy (transductal). Small stones (<5 mm) can be removed by a transcystic approach with a 3-mm choledochoscope or caught in a basket under fluoroscopy and retrieved via the cystic duct, or can be pushed through the papilla. A balloon to occlude the proximal duct whilst giving a smooth muscle relaxant, such as buscopan or glucagon, and then flushing through the balloon catheter can also be used to clear small distal duct stones. The transcystic approach is limited to stones small enough to be retrieved through the cystic duct (typically stones <5 mm) and it is not usually possible to access the proximal hepatic duct due to inability to retroflex the choledochoscope and other instruments.

p0345 Larger stones can be managed by a transductal approach by making a choledochotomy (a longitudinal incision in the anterior surface of the bile duct) and extracting stones by a combination

Approaches to the management of simultaneous CBD and gallbladder stones

s0115

Preoperative identification of CBD stones in the presence of gallbladder stones offers two principal management options – a two-stage preoperative clearance of the CBD followed by LC, or a single-stage LBDE and cholecystectomy. Several trials have shown that there is no significant difference in clinical outcomes between the two approaches.^{59–61} However, most studies show that single-stage LBDE is associated with a reduction in overall hospital stay when compared to the two-stage approach and has a lower overall cost.^{59,62} Furthermore, the complications of surgical duct exploration are predominantly related to choledochotomy (bile leak) and T-tube use (bile leakage, tube displacement) that has largely been replaced with primary bile duct closure, resulting in shorter operative time, reduced hospital length of stay, and faster return to work of approximately 8 days.⁶¹ UK national guidelines currently recommend that both approaches are considered equally valid treatment options and that training of surgeons in LBDE is to be encouraged.⁶³

LBDE is largely replacing open BDE, with approximately 80% of BDE now performed laparoscopically in England (HES data). However, for preoperatively identified stones, a US survey reported that 86% of surgeons would choose preoperative ERCP over BDE, and for intraoperatively discovered CBD stones, only 30% would choose LBDE, citing availability of ERCP, lack of equipment and lack of skill performing LBDE.⁶⁴

A third option that has been used in a few centres is the use of intraoperative ERCP at the time of

Chapter 11

LC.⁶⁵ Although feasible and with low morbidity, its use is not widespread due to the logistic difficulties of requiring ERCP equipment and staffing.

p0365 b0035

✔✔ Bile duct stones should be removed either by simultaneous bile duct exploration or perioperative ERCP depending on local resources and skills.

s0120

Approaches to abnormal LFTs prior to LC

p0370

The decision and desire of surgeons to identify the presence of stones in the CBD prior to LC is highly variable. There are now several different preoperative diagnostic techniques (MRCP and EUS) and intraoperative techniques for imaging (IOC and LUS), and several options to manage any common bile duct stones identified (pre-, intra-, or postoperative ERCP, open or laparoscopic BDE). At present, there are no studies to support one or other approach and it is therefore important to develop an individual strategy for the preoperative and operative management of patients with gallstones dependent upon the local availability of techniques and skills.

p0375

The financial and logistic implications of preoperative imaging of all patients undergoing LC would inflict a significant cost and strain on resources with currently around 100 000 procedures performed per annum in the UK and 600 00 in the USA, and would be of questionable benefit. Most clinicians will therefore attempt to stratify their patients in some way according to the probability of bile duct stones being present. Patients with normal LFTs, non-dilated bile ducts on ultrasound and no history of jaundice will have a <1.5% chance of having a common bile duct stone.⁶⁶ This low-risk group can undergo LC without the need for further preoperative imaging or intraoperative cholangiography, with an incidence of retained CBD stones of <1% and a very low risk of significant problems from retained stones.^{67,68}

p0380

Patients who are at highest risk of bile duct stones are those with jaundice at the time of surgery and those with preoperative US visualisation of a stone in the CBD (positive predictive value [PPV] of 0.86 and 0.74 at subsequent IOC). Another study found that patients with persistently abnormal LFTs, tested prior to MRCP with the presence of at least two of bilirubin >110 μmol/L, ALP >400 IU/L or ALT >750 IU/L together with a dilated CBD (>8 mm) or dilated IHDs, had a PPV of 87% for stones (compared to only 32% if the bile ducts were not dilated), and even less correlation with the presence of subsequently confirmed CBD stones when only the incident LFTs were used for prediction.⁶⁹

The combination of US duct dilatation and abnormal LFTs yields the next highest incidence of CBD stones preoperatively, e.g. the presence of two or more of: presentation with jaundice/bilirubin >20 mmol (2 g/dL), alkaline phosphatase 150 mmol, CBD >10 mm and/or a CBD stone seen on US, yielded a PPV for CBD stones of 56%. Similar findings were reported in patients with a history of jaundice and dilated ducts on preoperative US, with a PPV of 56%.⁶⁷ Thus, these criteria might be used to identify patients at intermediate risk of CBD stones to select for preoperative MRCP prior to preoperative ERCP, or for selection of patients for referral to a surgeon who performs single-stage LBDE. However, in a significant number of patients identified preoperatively with definite stones, at least 25% had passed stones spontaneously without problems by the time of surgery.⁶⁷

Less marked or singly elevated LFTs, particularly with non-dilated biliary ducts, have very poor sensitivity and specificity for predicting CBD stones, with an incidence in these groups of approximately 15–16% (Table 11.2).⁷⁰ This is only slightly higher than the incidence of CBD stones in the overall population of patients with symptomatic gallstones (9–13%).⁷¹ The choice between the various strategies in this low-risk group of patients at present depends largely upon the quality of the surgical and endoscopic therapies available, but ERCP should not be performed without prior demonstration of stones in this group.

Table 11.2 • Risk stratification for likelihood of CBD stones 10015

	Criteria	Relative risk of CBD stones
High risk	Preoperative US showing CBD stone Jaundice at time of procedure	0.74–0.86
Intermediate risk	At presentation, two of: Bilirubin >20 mmol/L ALP or AST/ALT >2–3 × normal Dilated CBD (>8 mm)	0.56
Low risk	History of jaundice + dilated ducts Single elevated ALP or AST/ALT	0.15
Minimal risk	History of acute gallstone pancreatitis Normal LFTs	0.01

CBD, common bile duct; LFTs, liver function tests; US, ultrasound.

p0395 There are three possible approaches to management of patients undergoing cholecystectomy with regard to the dilemma of the CBD and possible CBD stones:

o0010 1. Identification of CBD stones prior to LC in order to remove them by ERCP prior to surgery. This approach sets a threshold at which to perform MRCP based on abnormalities of LFTs ± - ultrasound findings. If stones are found at MRCP then ERCP can be performed and CBD stones removed. Most would then avoid intraoperative IOC. The disadvantage of this approach is a very high level of unnecessary MRCPs (around 85% depending on the threshold) and exposure to the risks of ERCP in the positive MRCP group.

o0015 2. Using preoperative stratification to perform selective IOC (or LUS) or alternatively simply performing routine IOC (or LUS) on all patients. If CBD stones are identified then the options are:

o0020 (a) Exploration of the bile duct with removal of the CBD stones intraoperatively by transcystic removal or choledochotomy.

o0025 (b) Secure closure of the cystic duct and perform postoperative ERCP.

p0420 The potential disadvantage of this approach is the risk of failure of ERCP to remove the CBD stones, although in practical terms this is <5%. Some surgeons place an antegrade stent at LC to further reduce this risk.

o0030 3. Not performing any pre- or intraoperative imaging and assessing patients on symptoms, or persistence of abnormal LFTs to select for postoperative CBD imaging.

p0430 It is clear that a small proportion of patients undergoing LC regardless of pre- or intraoperative investigations will thus have 'missed' CBD stones. The *potential* risks posed by these CBD stones are of subsequent acute gallstone pancreatitis, and postoperative bile leak due to CBD stone impaction and raised intrabiliary pressure causing clip failure in the first few days before the cystic duct has sealed. A study of 10 000 LC procedures in Switzerland identified that the immediate risk of acute postoperative pancreatitis was 0.34% and was due to CBD stones in only four patients (0.0004%).⁷² The incidence of CBD stones in patients with cystic duct stump leaks is only 3–5%,^{73,74} and thus neither of these concerns is significant.

p0435 Furthermore, several studies have shown that the incidence of symptoms relating to retained CBD stones is itself low and in fact not significantly different to the incidence of symptoms in patients who had undergone IOC with supposedly clear

ducts.^{75,76} The complication rate in these groups of patients with retained stones was very low.^{72,73}

The author's favoured approach is the use of p0440 preoperative imaging (MRCP) in the small group of patients presenting with gallbladder stones and obstructive jaundice (where the presence of CBD stones is >50%) and selective IOC in patients with acute gallstone pancreatitis or deranged LFTs. If stones are found on IOC, the favoured approach would be to proceed with LBDE for large stones if the CBD is >8 mm, or post-LC ERCP for small stones/small ducts (Fig. 11.12).

With so many options available, and with p0445 differences in availability of resources, this area requires further research to establish the best and most cost-effective approach. A large multicentre study in the UK is in progress (the Sunflower study).

✓ Patients with mild or moderately elevated LFTs can safely undergo laparoscopic cholecystectomy with intraoperative bile duct imaging or postoperative investigation of ongoing biliary symptoms, reducing the high number of unnecessary preoperative MRCPs. b0040 p0450

Management of specific scenarios s0125

Gallstone ileus s0130

Gallstone ileus (another misnomer) is not a p0455 dysfunction of motility but is a mechanical obstruction of the bowel caused by an impacted gallstone. It occurs as the result of an acutely inflamed gallbladder becoming adherent to a segment of bowel with subsequent inflammation and erosion of the stone through the bowel wall. The median age of affected patients is 70 years. It represents 1% of small bowel obstructions in patients <70 years, but 5% aged >70 years.⁷⁷ Presentation is with vomiting and abdominal distension and only rarely with acute cholecystitis. Half will have a preceding history of symptomatic gallstone disease. The stones are invariably large (>2.5 cm) and obstruction is most frequently at the level of the terminal ileum. Management following resuscitation is to remove the stone via a small enterotomy with primary closure of the bowel usually possible. Bowel resection is only necessary in the presence of perforation or ischaemia. Removal of the gallbladder is fraught with hazard due to the presence of the inflammation and cholecysto-enteric fistula. In most cases the stones have passed and the fistula closes spontaneously. Elective cholecystectomy and closure of the fistula is rarely necessary.⁷⁸

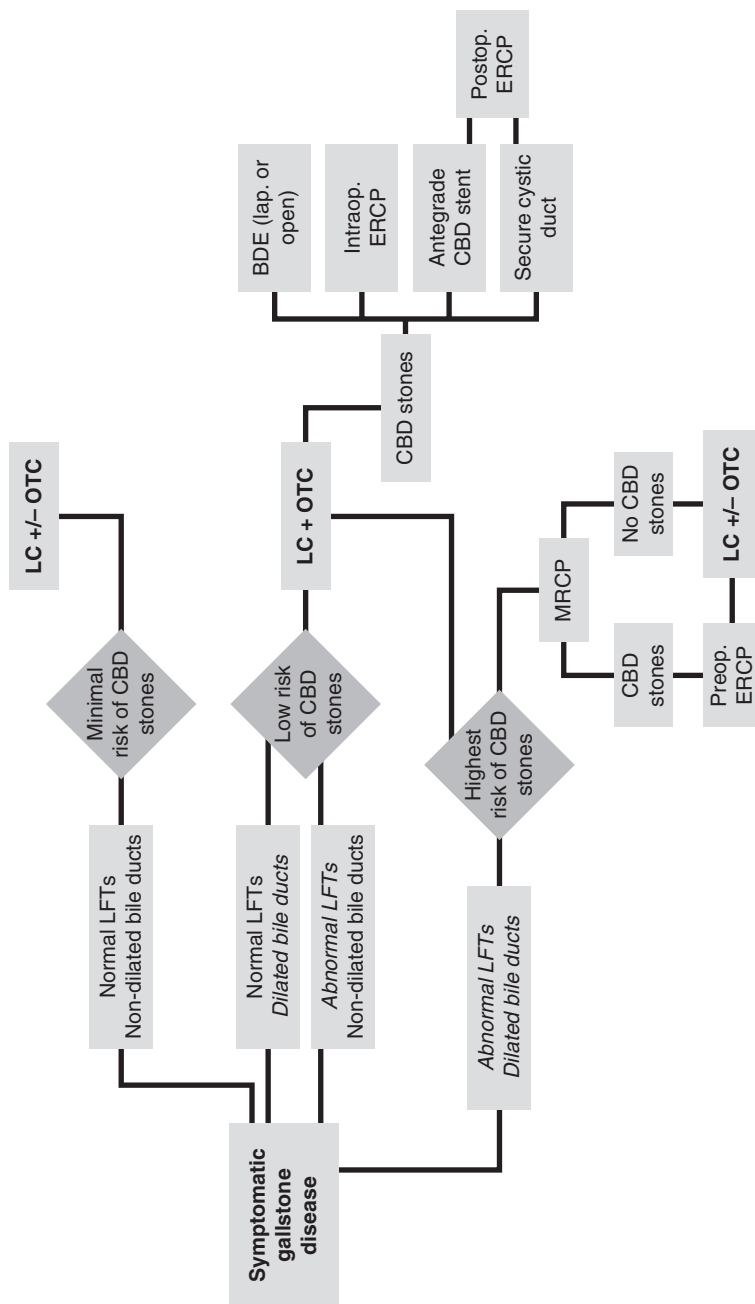


Figure 11.12 • Management algorithm for management of cholelithiasis.

f0065

s0135 **Mirizzi syndrome**

p0460 Type I Mirizzi syndrome can be managed by subtotal cholecystectomy with removal of the majority of the gallbladder leaving the posterior wall where it is adherent to the bile duct, and ligation of the cystic duct if identified and still patent. Sometimes no cystic duct is found and a drain is simply left in the gallbladder fossa in case a later leak does occur. Type II Mirizzi is defined by the presence of a fistula between the gallbladder and the bile duct due to erosion of the impacted gallbladder stone in Hartmann's pouch. There is usually a large amount of chronic inflammation present and primary closure and T-tube insertion rarely works. Typically, the CBD will need to be reconstructed with a Roux-en-Y hepaticojejunostomy (see Chapter 12).

s0140 **Postcholecystectomy complications – identification and management**

s0145 **Early presentation**

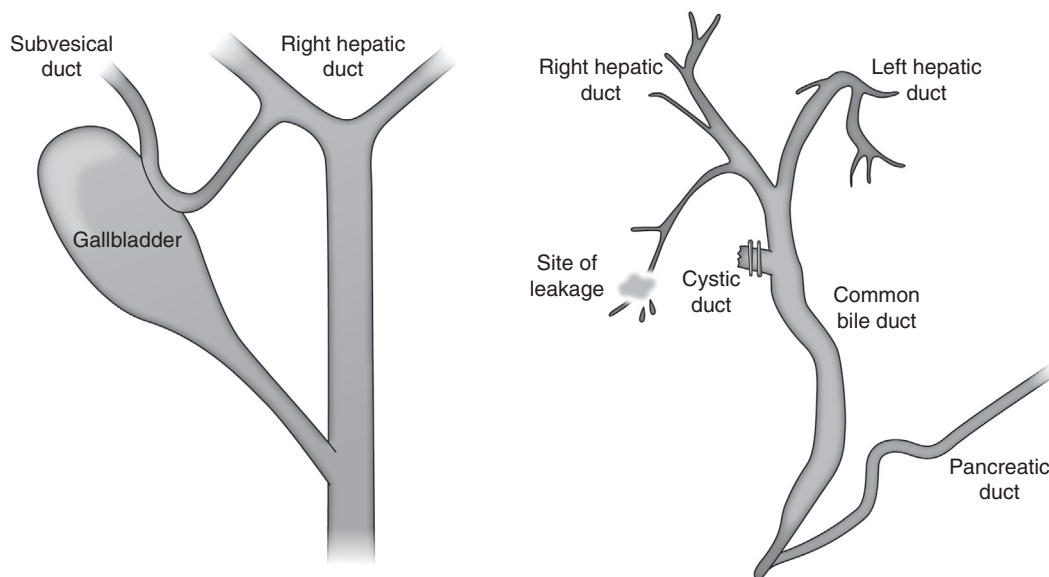
p0465 With the majority of LCs performed as day case procedures surgeons need to have a high index of suspicion for complications, and patients deviating from the normal pathway of early and rapid return to normal function within the first few hours or days of an elective cholecystectomy should be reviewed by an experienced surgeon.

Excessive pain in the early postoperative period p0470 may be an indicator of intraperitoneal leakage of bile or bowel contents. Significant hypotension and pain may be an indicator of bleeding. Early re-laparoscopy, to identify and correct these problems, is preferred to diagnostic imaging, which is likely to add delay and may be inconclusive.

Common sites of bleeding are from a slipped cystic p0475 artery clip or missed cystic artery, damage to the middle hepatic vein within the gallbladder bed of the liver, or damage to the superior epigastric vessels from port insertion. Bile leaks may be from slipped cystic duct clips, damage to the cystic duct during IOC, a duct of Luschka injury or injury to the main bile duct.

The duct of Luschka is a subvesical duct which p0480 lies within the gallbladder bed of the liver close to the surface and can be damaged during removal of the posterior gallbladder wall. These ducts are small and away from the porta hepatis. When a leak is identified it should be clipped or sutured to seal it and prevent ongoing leakage (Fig. 11.13). Failure to identify the exact source of a small bile leak should be managed by insertion of a drain. Most low volume leaks from a duct of Luschka will resolve with simple drainage. In prolonged drainage (>5 days), resolution may be expedited by ERCP and stent insertion. Persistent leakage requires formal identification of the damaged duct and suturing, or rarely, resection of a segment of liver and should be dealt with in a specialist hepatopancreaticobiliary (HPB) unit.

Cystic duct stump leak requires further clip p0485 application or suturing. Clips used to hold a



f0070 **Figure 11.13** • Anatomy of duct of Luschka injury.

Chapter 11

cholangiogram catheter in place can cause a small hole when removed and caution should be used to ensure that the lower most definitive clip is placed below the IOC cannula clip to prevent this.

p0490 Identification of a bile leak from the porta hepatis should be managed by insertion of a drain to the gallbladder fossa area, with discussion and early transfer to an HPB unit for investigation. The algorithm for investigation of a potential bile duct injury will depend on the timing post cholecystectomy, the presence or absence of sepsis and physiological well-being of the patient (see below).

p0495 b0045

✔ Patients who do not follow the normal pattern of straightforward recovery within the first 48 hours following cholecystectomy should be suspected of having a biliary leak until proven otherwise.

s0150

Delayed presentation

p0500

Patients who have been discharged home and re-present with ongoing or new onset of abdominal pain following LC should be investigated with assessment of full blood count and LFTs and consideration of CT. Ultrasound is rarely helpful in this setting due to the presence of RUQ tenderness and intra-abdominal gas. A small amount of gas and fluid in the gallbladder bed may be normal but collections of fluid or gas elsewhere may represent a bile leak. If haemostatic agents (e.g. Surgicel) have been used to control bleeding in the gallbladder bed there may be gas containing foreign material seen on US or CT. Elevated abnormal LFTs also raise suspicion of a bile leak or retained CBD stone. MRCP or ERCP will be diagnostic and the exact approach is dictated by the initial findings and clinical suspicion, the patient's condition and clinical urgency, and local availability and expertise. Concerns over MRI and dislodgement of cystic duct or artery clips in the immediate postoperative period are unfounded since virtually all metallic clips in current usage are non-ferrous.⁷⁹ The presence of bile collections or dilated intrahepatic ducts raises the suspicion of a bile duct injury and warrants early discussion and transfer to a specialist HPB unit.

p0505

Visualisation of a fluid collection in the presence of excessive pain, sepsis and/or abnormal LFTs should be evaluated with a percutaneous radiologically sited drain (or alternatively returned to theatre for laparoscopy). If bile is drained, an MRCP should be arranged to look for bile leakage or CBD stones with progression to ERCP if either is identified. If neither is identified and the patient is not septic then it is likely that the leak is small and will settle without further intervention and the drain can be removed once dry.

Retained CBD stones identified by MRCP in the postoperative period are best dealt with by ERCP. Success rates in most centres exceed 95% and recent developments of ultra-thin cholangioscopy (e.g. SpyGlass) permitting break-up of stones under direct vision using either electrohydraulic or laser lithotripsy are likely to increase this rate further.⁸⁰ LBDE can be performed in those where ERCP is not possible, e.g. large duodenal diverticulum, previous gastric bypass surgery.

✔ Patients re-presenting following cholecystectomy should undergo CT to look for a collection. In the presence of sepsis or significant abdominal pain, needle aspiration and subsequent drainage is mandated to look for a bile leak. b0050 p0515

Bile duct injury

s0155

It is widely held that the incidence of bile duct injuries increased twofold following the introduction of laparoscopic surgery to around 0.4%.⁸¹ Increasing recognition and the development and promulgation of techniques to prevent bile duct injury have reduced the rates to approximately 0.2–0.3%; however, this disguises the fact that there has been a significant incidence in more severe injuries in the laparoscopic group and a recognition that injury to the right hepatic artery is also present in approximately 25% of patients with a major bile duct injury.⁸²

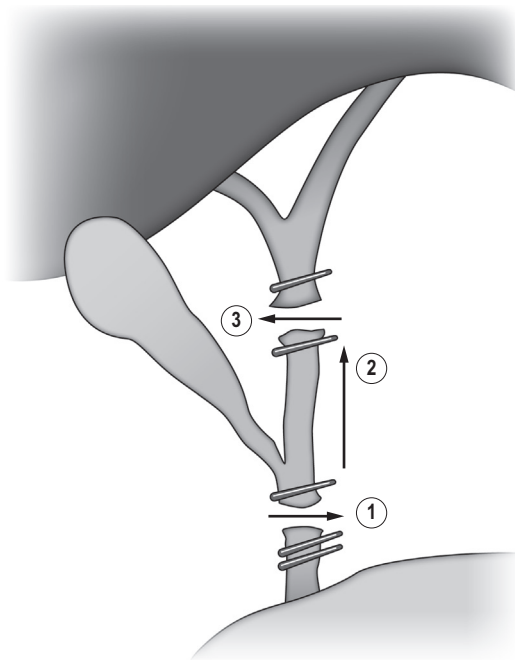
Davidoff described the mechanisms and errors involved in the causation of a 'classical' bile duct injury in the laparoscopic era. In this injury there is misidentification of the common duct for the cystic duct with subsequent ligation and division of the CBD, often with ligation of the right hepatic artery. This injury results in complete excision of a segment of the bile duct (Fig. 11.14).⁸³ The classification of bile duct injuries and their management is further discussed in Chapter 12. p0525

Postoperative problems (chronic)

s0160

Postoperative pain resolution following cholecystectomy is dependent upon case selection. Post-cholecystectomy pain is invariably the result of precholecystectomy symptoms/other diagnoses and there is no evidence that the procedure of LC in itself results in the development of abdominal pain. p0530

A proportion of patients (approximately 5%) develop looser bowel habit or urgency of defaecation, although this is usually in patients who had some degree of symptoms (e.g. irritable bowel syndrome) pre-LC. Severe high volume diarrhoea p0535



f0075 **Figure 11.14** • The 'classical' bile duct injury. Excessive cephalad retraction of the gallbladder leads to dissection of the CBD low down (1). Subsequent mobilisation of the bile duct occurs (2). Removal of the gallbladder specimen requires further division of the bile duct (3) and, in around 25% of cases, division of the RHA as well. Adapted from Davidoff AM, Pappas TN, Murray EA, et al. Mechanisms of major biliary injury during laparoscopic cholecystectomy. *Ann Surg* 1992;215(3):196–202.

is fortunately extremely rare.^{84,85} Loose stools may be due to the more constant flow of bile entering a relatively empty bowel resulting in irritation of the bowel rather than a bolus of bile delivered by the contraction of the gallbladder in response to cholecystokinin into a small bowel containing fat. In half of these patients a degree of adaptation appears to occur with resolution of symptoms over a period of 3–6 months. Patients who continue to be troubled with diarrhoea may benefit from loperamide to control urgency and/or a bile-binding agent such as cholestyramine.⁸⁶

p0540 Gallstones which are dropped at the time of cholecystectomy as a result of perforation of the gallbladder are quite commonly seen with an estimated incidence of spilled stones in approximately 7% of LCs, and of stones definitely left within the peritoneal cavity of approximately 2%.⁸⁷ Complications of dropped stones are, however, uncommon. The commonest complication of dropped stones is the development of an intra-abdominal abscess which occurs in 0.1–2.9% of patients with dropped stones at an average of 14 months after surgery.⁸⁸ Some of these present with subphrenic abscess formation requiring repeat laparoscopy or laparotomy to drain the pus and find the causative stone(s). The stones themselves may

be very small but can usually be identified on CT. Attempts should therefore be made to remove all spilled stones where possible although conversion to laparotomy is not considered advisory to achieve complete clearance.

Gallstones and cancer

s0165

A number of studies purported to show both positive p0545 and negative associations between gallstones or cholecystectomy and various non-biliary tract cancers, in particular with the development of gastrointestinal tract cancers. A large population-based study in the USA suggests that there may be a slight increase in liver, pancreatic and gastro-oesophageal cancers but a decrease in colorectal cancers. Whether these increases are true or occur by chance, the risk ratios are small and insufficient to advise a change of practice either way.⁸⁹

There is an association between gallstones and the p0550 development of gallbladder cancers, with a relative risk of 4.9.⁹⁰ The relative risk is further increased from 2.4 in patients with stones <3 cm, to 10 with stones >3 cm. However, there is no justification for removal of the gallbladder based solely on concerns over the risk of developing gallbladder cancer.

s0170 **Porcelain gallbladder**

p0555 Extensive calcium encrustation of the gallbladder wall is referred to as porcelain gallbladder. The incidence of porcelain gallbladder is reported to be 0.6–0.8%, with a male-to-female ratio of 1:5. Most porcelain gallbladders (90%) are associated with gallstones.^{91,92} Patients with a porcelain gallbladder are asymptomatic, and the condition is usually found incidentally on plain abdominal radiographs, US or CT imaging. Surgical treatment of porcelain gallbladder is based on results from studies performed between 1931 and 1973, which demonstrated a very high frequency (22–68%) of adenocarcinoma in porcelain gallbladder.⁹³

p0560 However, the causal relationship between porcelain gallbladder and malignancy has not been established and the very high rates of carcinoma originally quoted seem, for whatever reason, to be less high than previously recorded in more recent case series (i.e. dating from 2001–11) that show incidences ranging from 2.3% to 7%.^{94,95} Current guidance is that patients found to have porcelain gallbladder should undergo LC to prevent the risk of developing gallbladder cancer.

s0175 **Other diseases of the gallbladder**

s0180 **Acute acalculous cholecystitis**

p0565 Acute acalculous cholecystitis is a life-threatening condition that occurs in critically ill patients. It is an uncommon problem encountered largely in patients in intensive care or in cardiac patients as a result of poor perfusion. The cystic artery is an end-organ artery with no collateral circulation and poor perfusion can result in gallbladder ischaemia with resultant pain and tenderness. The diagnosis is often elusive and the condition is associated with significant mortality (up to 50%). Risk factors include severe trauma or burns, major surgery such as cardiopulmonary bypass, prolonged fasting, total parenteral nutrition, sepsis, diabetes mellitus, atherosclerotic disease, systemic vasculitis, acute renal failure and acquired immunodeficiency syndrome (AIDS). The condition is thought to be caused by microvascular occlusion of end arteries within the gallbladder wall resulting in ischaemia and, in up to 60% of cases, in gangrene.⁹⁶ Over 70% of patients have atherosclerotic disease, which might explain the higher prevalence of the condition in elderly men.⁹⁷

p0570 The diagnosis of acute acalculous cholecystitis is often hindered by obtundation of the patient, the presence of pre-existing diseases or recent abdominal surgery, and requires a high index of suspicion. Ultrasound confirms the diagnosis

within the intensive care unit and allows immediate percutaneous cholecystostomy which reduces the tension on the gallbladder wall and has become the preferred alternative to cholecystectomy in the treatment of the condition in severely ill patients.⁹⁸ Early cholecystectomy may still be appropriate depending on the patient's clinical condition and if cholecystostomy fails to improve the patient's conditions, as gangrene can develop with subsequent perforation of the gallbladder.

Primary infections of the gallbladder

s0185

Primary infective cholecystitis is rare and is more commonly seen in immunocompromised patients. Typical causative organisms include *Salmonella typhi*, *Campylobacter jejuni* and *Vibrio cholera*. The presentation is similar to patients with acute acalculous cholecystitis, but there is often an antecedent history of a gastroenteritis-like illness.

AIDS patients are susceptible to opportunistic gastrointestinal infections including acute cholecystitis and cholangitis, especially when the CD4 count falls below 200. In half the cases there are no associated gallstones within the biliary tract. The most common infecting agents are cytomegalovirus and cryptosporidium, and less commonly *Candida*, fungi and *Mycobacterium tuberculosis*. The 30-day mortality in AIDS patients with acute cholecystitis is 20%.

Treatment is by appropriate intravenous antibiotics followed by laparoscopic cholecystectomy.

Chronic acalculous cholecystitis

s0190

Chronic acalculous cholecystitis is a poorly understood condition. The term is used to describe patients with biliary pain but without cholelithiasis. In some cases biliary sludge may be responsible for a localised inflammatory response in the gallbladder with pain and tenderness typical of low-grade biliary pain. Occasionally a tiny stone within the spiral valve of the cystic duct is found at cholecystectomy which was missed preoperatively.

In patients with typical biliary pain, cholecystectomy may be justifiable in the absence of other disease processes and treatment options. Informed consent with an understanding of at best a 50% likelihood of pain resolution must be emphasised.

Isotope scans with HIDA or DISIDA (cholescintigraphy) have been used to improve outcomes in this group by selecting patients with a non-functioning gallbladder (failure to take up isotope within 4 hours of injection) or poorly functioning gallbladder. The gallbladder ejection fraction (GBEF) is used to calculate gallbladder function by giving

a cholecystokinin (CCK) analogue or fatty meal following uptake of the isotope by the gallbladder. These stimulate emptying of the gallbladder, allowing an ejection fraction to be calculated. Administration of CCK may also recreate the pain. Normal GBEF is around 75% and LC in patients with low gallbladder ejection fractions (<40%) achieves long-term symptom relief in 65–80% of cases.^{99,100}

It occurs at any age from 1 month to 15 years¹⁰³ and is frequently misdiagnosed as appendicitis. Cholecystostomy is the treatment of choice.

Adenomyomatosis

s0200

Adenomyomatosis of the gallbladder is an acquired, p0615 hyperplastic lesion characterised by excessive proliferation of the gallbladder mucosa with invaginations into the muscle layer to produce deep clefts (Rokitansky–Aschoff sinuses). It may be generalised or localised to one area (adenomyoma). The involved gallbladder wall is thickened to 10 mm or greater. Gallstones are found in 60% of cases. It is usually an incidental radiological or pathological finding and simple adenomyomatosis is not considered a premalignant condition.

In the absence of biliary tract symptoms, adeno- p0620 myomatosis requires no treatment. If the patient has biliary pain and evidence of adenomyomatosis with calculi, a cholecystectomy is indicated. The benefit of LC in patients with biliary pain and adenomyomatosis but no gallstones is more difficult to predict but the likelihood of benefit from surgery increases the more extensive or severe the adenomyomatosis.¹⁰⁴


s0195 Gallbladder disease in childhood

p0605 Underlying conditions are identified in 60% of children presenting with gallstones. These include haemolytic anaemias, congenital anomalies (choledochal cyst, prematurity, NEC), genetic disorders (Down syndrome, cystic fibrosis), Crohn's disease and ileal resection, liver disease and cirrhosis, cancer or leukaemia therapy.¹⁰¹ Obesity is becoming an increasingly important risk factor in development of childhood cholelithiasis. Overall, the risk of gallstones in children is 0.13% (0.27% in females). Management is similar to that of adults, with LC.¹⁰² CBD stones are the commonest cause of obstructive jaundice in children.

p0610 Acalculous cholecystitis in children may follow burns and trauma and may also be seen as a postoperative complication of abdominal surgery.

b0055 Key points

- u0060 • Biliary pain is typically epigastric/right upper quadrant pain, radiating around or through to the back, lasting >20 minutes, often occurring at night or associated with eating fatty foods.
- u0065 • People with gallstones but without symptoms do not require further management or follow-up.
- u0070 • People with gallstones and biliary pain should be offered laparoscopic cholecystectomy as definitive treatment to prevent further episodes of pain and development of complications.
- u0075 • Laparoscopic cholecystectomy is one of the commonest general surgical procedures in the UK, with around 100 000 procedure performed in England per annum.
- u0085 • Current advice is to remove all CBD stones, which can be done most cost-effectively by simultaneous laparoscopic bile duct exploration but is still most frequently done by ERCP.
- u0090 • Following cholecystectomy, patients presenting with abdominal pain in the first 48 hours should be investigated quickly to identify potential biliary leaks/bile duct injury.

p0665 b0060  Full references available at <http://expertconsult.inkling.com>

bi0010 Key references

- bb0010 29. Reynolds W. The first laparoscopic cholecystectomy. *J Soc Laparoend Surg* 2001;5:89–94. [Good review of the early history of laparoscopic cholecystectomy.](#)
- bb0015 44. Strasberg SM, Brunt LM. Rationale and use of the critical view of safety in laparoscopic cholecystectomy. *J Am Coll Surg* 2010;211:132–8. PMID: 20610259.

Essential reading for rationale and technique of safe cholecystectomy avoiding bile duct injury.

63. Williams EJ, Green J, Beckingham I, et al. Updated guidelines on the management of common bile duct stones (CBDS). *Gut* 2017;66(5):765–82. PMID: 28122906. [Definitive guidelines on current diagnosis and management of CBD stones.](#) bb0020
83. Davidoff AM, Pappas TN, Murray EA, et al. Mechanisms of major biliary injury during laparoscopic cholecystectomy. *Ann Surg* 1992;215(3):196–202. PMID: 1531913. [Analysis of causes of bile duct injury during laparoscopic cholecystectomy.](#) bb0025

Non-Print Items

References

1. Nam-Sik S. Life without a gallbladder. Seoul College of Veterinary Medicine News & Forum; SNU Media, February 17, 2009.
2. Mills JC, Stappenbeck TS, Bunnett NW. Gastrointestinal disease. In: McPhee SJ, Hammer GD, editors. Pathophysiology of disease: an introduction to clinical medicine. 6th ed. New York: McGraw-Hill Medical; 2010.
3. Marschall HU, Einarsson C. Gallstone disease. *J Intern Med* 2007;261:529–42. PMID: 17547709.
4. Bar Dayan Y, Vilkin A, Niv Y. Gallbladder mucin plays a role in gallstone formation. *Eur J Intern Med* 2004;15(7):411–4. PMID: 15581743.
5. Kalloo AN, Kantsevov SV. Gallstones and biliary disease. *Prim Care* 2001;28:591–606. PMID: 11483446.
6. van der Linden W, Simonson N. Familial occurrence of gallstone disease incidence in parents of young patients. *Hum Hered* 1973;23:123–7. PMID: 4756851.
7. Lammert F, Sauerbruch T. Mechanisms of disease: the genetic epidemiology of gallbladder stones. *Nat Clin Pract Gastroenterol Hepatol* 2005;2(9):423–33. PMID: 16265433.
8. Cuevas A, Miquel JF, Reyes MS, et al. Diet as a risk factor for cholesterol gallstone disease. *J Am Coll Nutr* 2004;23:187–96. PMID: 15190042.
9. Valdivieso V, Covarrubias C, Siegel F, et al. Pregnancy and cholelithiasis: pathogenesis and natural course of gallstones diagnosed in early puerperium. *Hepatology* 1993;17:1–4. PMID: 8423030.
10. Stampfer M, Maclure K, Colditz G, et al. Risk of symptomatic gallstones in women with severe obesity. *Am J Clin Nutr* 1992;55:652–8. PMID: 1550039.
11. Stinton LM, Shaffer EA. Epidemiology of gallbladder disease: cholelithiasis and cancer. *Gut Liver* 2012;6(2):172–87. PMID: 22570746.
12. Behar J, Corazziari E, Guelrud M, et al. Functional gallbladder and sphincter of Oddi disorders. *Gastroenterology* 2006;130:1498–509. PMID: 16678563.
13. Weinert CR, Arnett D, Jacobs Jr, D, et al. Relationship between persistence of abdominal symptoms and successful outcome after cholecystectomy. *Arch Intern Med* 2000;160:989–95. PMID: 10761964.
14. Vetrhus M, Berhane T, Søreide O, et al. Pain persists in many patients five years after removal of the gallbladder: observations from two randomized controlled trials of symptomatic, noncomplicated gallstone disease and acute cholecystitis. *J Gastrointest Surg* 2005;9:826–31. PMID: 15985239.
15. Thistle J, Cleary P, Lachin J, et al. The natural history of cholelithiasis: the National Cooperative Gallstone Study. *Ann Intern Med* 1984;101:171–5. PMID: 6742647.
16. Newman H, Northup J, Rosenblum M, et al. Complications of cholelithiasis. *Am J Gastroenterol* 1968;50:476–96. PMID: 5704290.
17. Ransohoff D, Gracie W. Treatment of gallstones. *Ann Intern Med* 1993;119:606–19. PMID: 8363172.
18. Lefemine V, Morgan RJ. Spontaneous passage of common bile duct stones in jaundiced patients. *Hepatobiliary Pancreat Dis Int* 2011;10(2):209–13. PMID: 21459730.
19. Collins C, Maguire D, Ireland A, et al. A prospective study of common bile duct calculi in patients undergoing laparoscopic cholecystectomy: natural history of choledocholithiasis revisited. *Ann Surg* 2004;239(1):28–33. PMID: 14685097.
20. Giljaca V, Gurusamy KS, Takwoingi Y, et al. Endoscopic ultrasound versus magnetic resonance cholangiopancreatography for common bile duct stones. *Cochrane Database Syst Rev* 2015;(2). PMID: 25719224.
21. Chetana Vaishnavi. Infections of the gastrointestinal system. JP Medical Ltd; 2013. p. 511.
22. Vitek L, Carey MC. New pathophysiologic concepts underlying pathogenesis of pigment gallstones. *Clin Res Hepatol Gastroenterol* 2012;36(2):122–9. PMID: 21978438.
23. Beckingham IJ, Krige JEJ, Bornman PC, et al. Hepaticojejunal biliary access loop for the management of intrahepatic stones. *Br J Surg* 1998;85:1360–3. PMID: 9782013.
24. Chu KM, Lo CM, Liu CL, et al. Malignancy associated with hepatolithiasis. *Hepatogastroenterology* 1997;44:352–7. PMID: 9164501.
25. Thistle JL, Cleary PA, Lachin JM, et al. The natural history of cholelithiasis: the National Cooperative Gallstone Study. *Ann Intern Med* 1984;101:171–5. PMID: 6742647.
26. Friedman GD. Natural history of asymptomatic and symptomatic gallstones. *Am J Surg* 1993;165:399–404. PMID: 8480871.
27. Bouchier IA. Non-surgical treatment of gallstones: many contenders but who will win the crown? *Gut* 1988;29:137–42. PMID: 3278953.
28. Moran P. The truth about gallbladder and liver 'flushes'. <http://www.quackwatch.com/01QuackeryRelatedTopics/flushes.html>.
29. Reynolds W. The first laparoscopic cholecystectomy. *J Soc Laparoend Surg* 2001;5:8–94. [Good review of the early history of Laparoscopic cholecystectomy.](#)
30. Andren-Sandberg A, Alinder A, Bengmark S. Accidental lesions of the common bile duct at

Non-Print Items

- cholecystectomy: pre- and per-operative factors of importance. *Ann Surg* 1985;201:328–33. PMID: 3977435.
31. Banting S, Carter DC. Expectations of cholecystectomy. In: Paterson-Brown S, Garden J, editors. Principles and practice of surgical laparoscopy. London: WB Saunders; 1994. p. 53–66.
 32. Dunn D, Fowler S, Nair R, et al. Laparoscopic cholecystectomy in England and Wales: results of an audit by the Royal College of Surgeons of England. *Ann R Coll Surg Engl* 1994;76:269–75. PMID: 8074391.
 33. Steele RJ, Marshall K, Lang M, et al. Introduction of laparoscopic cholecystectomy in a large teaching hospital: independent audit of the first 3 years. *Br J Surg* 1995;82:968–71. PMID: 7648122.
 34. Underwood RA, Soper NJ. Laparoscopic cholecystectomy and choledocholithotomy. In: Bumgart LH, Fong Y, editors. Surgery of the liver and biliary tract. London: WB Saunders; 2000. ch. 38.
 35. Croce E, Azzola M, Golia M, et al. Laparoscopic cholecystectomy 6,865 cases from Italian institutions. *Surg Endosc* 1994;8:1088–9. PMID: 7992182.
 36. Moore M, Bennett C. The learning curve for laparoscopic cholecystectomy. The Southern Surgeons Club. *Am J Surg* 1995;170:55–9. PMID: 7793496.
 37. Gigot J-F, Etienne J, Aerts R, et al. The dramatic reality of biliary tract injury during laparoscopic cholecystectomy. An anonymous multicenter Belgian survey of 65 patients. *Surg Endosc* 1997;12:1171–8. PMID: 9373288.
 38. Fransen S, Stassen L, Bouvy N. Single incision laparoscopic cholecystectomy: a review on the complications. *J Minimal Access Surg* 2012;8(1):1–5. PMID: 22303080.
 39. Bingener J, Gostout CJ. Update on natural orifice transluminal endoscopic surgery. *Gastroenterol Hepatol* 2012;8(6):384–9. PMID: 22933874.
 40. Flum DR, Dellinger EP, Cheadle A, et al. Intraoperative cholangiography and risk of common bile duct injury during cholecystectomy. *JAMA* 2003;289:1639–44. PMID: 12672731.
 41. Giger U, Ouaiissi M, Schmitz SF, et al. Bile duct injury and use of cholangiography during laparoscopic cholecystectomy. *Br J Surg* 2011;98(3):391–6. PMID: 21254014.
 42. Tranter SE, Thompson MH. A prospective single-blinded controlled study comparing laparoscopic ultrasound of the common bile duct with operative cholangiography. *Surg Endosc* 2003;17:216–9. PMID: 12457223.
 43. Boni L, David G, Mangano A, et al. Clinical applications of indocyanine green (ICG) enhanced fluorescence in laparoscopic surgery. *Surg Endosc* 2015;29(7):2046–55. PMID: 25303914.
 44. Strasberg SM, Brunt LM. Rationale and use of the critical view of safety in laparoscopic cholecystectomy. *J Am Coll Surg* 2010;211:132–8. PMID: 20610259.
Essential reading for rationale and technique of safe cholecystectomy avoiding bile duct injury.
 45. Averginos C, Kelgiorgi D, Touloumis Z, et al. One thousand laparoscopic cholecystectomies in a single surgical unit using the ‘critical view of safety’ technique. *J Gastrointest Surg* 2009;13:498–503. PMID: 19009323.
 46. Yegiyants S, Collins JC. Operative strategy can reduce the incidence of bile duct injury in laparoscopic cholecystectomy. *Am Surg* 2008;74:985–7. PMID: 18942628.
 47. Elshaer M, Gravante G, Thomas K, et al. Subtotal cholecystectomy for ‘difficult gallbladders’. Systematic review and meta-analysis. *JAMA Surg* 2015;150(2):159–68. PMID: 25548894.
 48. Viste A, Horn A, Øvrebø K, et al. Bile duct injuries following laparoscopic cholecystectomy. *Scand J Surg* 2015;104(4):233–7. PMID: 25700851.
 49. Way LW, Stewart L, Gantert W, et al. Causes and prevention of laparoscopic bile duct injuries: analysis of 252 cases from a human factors and cognitive psychology perspective. *Ann Surg* 2003;237(4):460–9. PMID: 12677139.
 50. Akriviadis EA, Hatzigavriel M, Kapnias D, et al. Treatment of biliary colic with diclofenac: a randomised, double blind, placebo-controlled study. *Gastroenterology* 1997;113:225–31. PMID: 9207282.
 51. Ansaloni L, Pisano M, Coccolini F, et al. WSES guidelines on acute calculous cholecystitis. *World J Emerg Surg* 2016;11:25. PMID: 27307785.
 52. Okamoto K, Takada T, Strasberg SM, et al. TG13 management bundles for acute cholangitis and cholecystitis. *J Hepatobiliary Pancreat Sci* 2013;20:55–9. PMID: 23307002.
 53. Tranter SE, Thompson MH. Comparison of endoscopic sphincterotomy and laparoscopic exploration of the common bile duct. *Br J Surg* 2002;89:1495–504. PMID: 12445057.
 54. Rhodes M, Sussman L, Cohen L, et al. Randomised trial of laparoscopic exploration of common bile duct versus postoperative endoscopic retrograde cholangiography for common bile duct stones. *Lancet* 1998;351:159–61. PMID: 9449869.
 55. Cuschieri A, Lezoche E, Morino M, et al. EAES multicenter prospective randomized trial comparing two-stage vs single-stage management of patients with gallstone disease and ductal

Non-Print Items

- calculi. *Surg Endosc* 1999;13:952–7. PMID: 10526025.
56. Varban O, Assimos D, Passman C, et al. Video. Laparoscopic common bile duct exploration and holmium laser lithotripsy: a novel approach to the management of common bile duct stones. *Surg Endosc* 2010;24:1759–64. PMID: 20177943.
57. Waage A, Stromberg C, Leijonmarck CE, et al. Long-term results from laparoscopic common bile duct exploration. *Surg Endosc* 2003;17:1181–5. PMID: 12739114.
58. Riciardi R, Islam S, Canete JJ, et al. Effectiveness and long-term results of laparoscopic common bile duct exploration. *Surg Endosc* 2003;17:19–22. PMID: 12399840.
59. Cuschieri A, Lezoche E, Morino M, et al. EAES multicenter prospective randomized trial comparing two-stage vs single-stage management of patients with gallstone disease and ductal calculi. *Surg Endosc* 1999;13(10):952–7. PMID: 10526025.
60. Zhang HW, Chen YJ, Wu CH, et al. Laparoscopic common bile duct exploration with primary closure for management of choledocholithiasis: a retrospective analysis and comparison with conventional T-tube drainage. *Am Surg* 2014;80:178–81. PMID: 24480219.
61. Gurusamy KS, Koti R, Davidson BR. T-tube drainage versus primary closure after laparoscopic common bile duct exploration. *Cochrane Database Syst Rev*;6:CD005641.
62. Rhodes M, Sussman L, Cohen L, et al. Randomised trial of laparoscopic exploration of common bile duct versus postoperative endoscopic retrograde cholangiography for common bile duct stones. *Lancet* 1998;351:159–61. PMID: 9449869.
63. Williams EJ, Beekingham I, El Sayad G, et al. Updated guidelines on the management of common bile duct stones (CBDs). *Gut* 2017;66(5):765–82. PMID: 28122906.
- Definitive guidelines on current diagnosis and management of CBD stones.**
64. Petelin JB. Laparoscopic common bile duct exploration. *Surg Endosc* 2003;11:1705–15.
65. Gurusamy K, Sahay SJ, Burroughs AK, et al. Systematic review and meta-analysis of intraoperative versus preoperative endoscopic sphincterotomy in patients with gallbladder and suspected common bile duct stones. *Br J Surg* 2011;98:908–16. PMID: 21472700.
66. Somnay K, Carr-Locke DL. Stones in the bile duct: endoscopic approaches. In: Bumgart LH, Fong Y, editors. *Surgery of the liver and biliary tract*. London: WB Saunders; 2000. ch. 40.
67. Horwood J, Akbar F, Davis K, et al. Prospective evaluation of a selective approach to cholangiography for suspected common bile duct stones. *Ann R Coll Surg Engl* 2010;92(3):206–10. PMID: 20223077.
68. Thornton DJA, Robertson A, Alexander DJ. Laparoscopic cholecystectomy without routine operative cholangiography does not result in significant problems related to retained stones. *Surg Endosc* 2002;16:592. PMID: 11972195.
69. Isherwood J, Garcea G, Williams R, et al. Serology and ultrasound for diagnosis of choledocholithiasis. *Ann R Coll Surg Engl* 2014;96:224–8. PMID: 24780789.
70. Gurusamy KS, Giljaca V, Takwoingi Y, et al. Ultrasound versus liver function tests for diagnosis of common bile duct stones. *Cochrane Database Syst Rev* 2015;Feb 26(2):CD011548. PMID: 25719223.
71. Alponat A, Kum CK, Rajnakova K, et al. Predictive factors for synchronous common bile duct stones in patients with cholelithiasis. *Surg Endosc* 1997;11(9):928–32. PMID: 9294275.
72. Z'graggen K, Aronsky D, Maurer CA, et al. Acute postoperative pancreatitis after laparoscopic cholecystectomy. Results of the Prospective Swiss Association of Laparoscopic and Thoracoscopic Surgery Study. *Arch Surg* 1997;132(9):1026–30. PMID: 9301618.
73. Deziel DJ, Millikan KW, Economou SG, et al. Complications of laparoscopic cholecystectomy: a national survey of 4,292 hospitals and an analysis of 77,604 cases. *Am J Surg* 1993;165(1):9–14. PMID: 8418705.
74. Wise Unger S, Glick GL, Landeros M. Cystic duct leak after laparoscopic cholecystectomy: a multi-institutional study. *Surg Endosc* 1996;10(12):1189–93. PMID: 8939840.
75. Ford JA, Soop M, Du J, et al. Systematic review of intraoperative cholangiography in cholecystectomy. *Br J Surg* 2012;99(2):160–7. PMID: 22183717.
76. Sajid M, Leaver C, Haider Z, et al. Routine on-table cholangiography during cholecystectomy: a systematic review. *Ann R Coll Surg Engl* 2012;94(6):375–80. PMID: 22943325.
77. Zaliakas J, Munson JL. Complications of gallstones: the Mirizzi syndrome, gallstone ileus, gallstone pancreatitis, complications of 'lost' gallstones. *Surg Clin North Am* 2008;88:1345–68. PMID: 18992599.
78. Reisner RM, Cohen JR. Gallstone ileus: a review of 1001 reported cases. *Am Surg* 1994;60:441–6. PMID: 8198337.
79. MRI Safety.com. Information resource for MRI safety, bioeffects and patient management. [Online]. www.mrisafety.com.
80. Moon JH, Ko BM, Choi HJ, et al. Direct peroral cholangioscopy using an ultra-slim upper endoscope for the treatment of retained bile duct

Non-Print Items

- stones. *Am J Gastroenterol* 2009;104:2729–33. PMID: 19623165.
81. Wu YV, Linehan DC. Bile duct injuries in the era of laparoscopic cholecystectomies. *Surg Clin* 2010;4:787–802. PMID: 20637948.
82. Strasberg SM, Helton WS. An analytical review of vasculobiliary injury in laparoscopic and open cholecystectomy. *HPB* 2011;13(1):1–14. PMID: 21159098.
83. Davidoff AM, Pappas TN, Murray EA, et al. Mechanisms of major biliary injury during laparoscopic cholecystectomy. *Ann Surg* 1992;215(3):196–202. PMID: 1531913. [Analysis of causes of bile duct injury during laparoscopic cholecystectomy.](#)
84. Hearing SD, Thomas LA, Heaton KW, et al. Biliary and pancreatic disease: effect of cholecystectomy on bowel function: a prospective, controlled study. *Gut* 1999;45:6889–94. PMID: 10562588.
85. O'Donnell LJ. Post-cholecystectomy diarrhoea: a running commentary. *Gut* 1999;45:796–7. PMID: 10562574.
86. Farahmandfar M, Chabok M, Alade M, et al. Post-cholecystectomy diarrhea – a systematic review. *Surg Sci* 2012;3:332–8.
87. Woodfield JC, Rodgers M, Windsor JA. Peritoneal gallstones following laparoscopic cholecystectomy: incidence, complications and management. *Surg Endosc* 2004;18:1200–7. PMID: 15457378.
88. Castellon-Pavon CJ, Morales-Artero S, Martinez-Pozuelo A, et al. Complications due to spilled gallstones and surgical clips during laparoscopic cholecystectomy. *Cir Esp* 2008;84:3–9. PMID: 18590668.
89. Nogueira L, Freedman ND, Engels EA, et al. Gallstones, cholecystectomy and risk of digestive system cancers. *Am J Epidemiol* 2014;179(6):731–9. PMID: 24470530.
90. Randi G, Franceschi S, La Vecchia C. Gallbladder cancer world-wide: geographical distribution and risk factors. *Int J Cancer* 2006;118:1591–602. PMID: 16397865.
91. Dähnert W. *Radiology review manual*. 6th edition. Philadelphia: Wolters Kluwer Health; 2006. p. 743.
92. Liang HP, Cheung WK, Su FH, et al. Porcelain gallbladder. *J Am Geriatr Soc* 2008;56(5):960–1. PMID: 18454764.
93. Berk RN, Armbuster TG, Saltzstein SL. Carcinoma in the porcelain gallbladder. *Radiology* 1973;106:29–31. PMID: 4682728.
94. Stephen AE, Berger DL. Carcinoma in the porcelain gallbladder: a relationship revisited. *Surgery* 2001;129(6):699–703. PMID: 11391368.
95. Khan ZS, Livingston EH, Huerta S. Reassessing the need for prophylactic surgery in patients with porcelain gallbladder: case series and systematic review of the literature. *Arch Surg* 2011;146:1143. PMID: 22006872.
96. Kalliafas S, Ziegler DW, Flancaum L, et al. Acute acalculous cholecystitis, risk factors, diagnosis and outcome. *Am Surg* 1998;64:471–5. PMID: 9585788.
97. Savoca PE, Longo WE, Pasternak B, et al. Does visceral ischaemia play a role in the pathogenesis of acute acalculous cholecystitis? *J Clin Gastroenterol* 1990;12:33–6. PMID: 2303685.
98. Berger H, Pratschke E, Arbogast H, et al. Percutaneous cholecystostomy in acute acalculous cholecystitis. *Hepatogastroenterology* 1989;36:346–8. PMID: 2620902.
99. Yap L, Wycherley A, Morphett A, et al. Acalculous biliary pain: cholecystectomy alleviates symptoms in patients with abnormal cholescintigraphy. *Gastroenterology* 1991;3:786–93. PMID: 1860640.
100. Rastogi A, Slivka A, Moser A, et al. Controversies concerning pathophysiology and management of acalculous biliary-type abdominal pain. *Dig Dis Sci* 2005;50:1391–401. PMID: 16110827.
101. Bogue CO, Murphy AJ, Gerstle JT, et al. Risk factors, complications, and outcomes of gallstones in children: a single-center review. *J Pediatr Gastroenterol Nutr* 2010;50:303–8. PMID: 20118803.
102. Davenport M, Howard ER. In: Howard ER, editor. *Surgery of liver disease in children*. London: Butterworth-Heinemann; 1991. p. 91.
103. Cuschieri A, Bobois F, Mouiel J, et al. The European experience with laparoscopic cholecystectomy. *Am J Surg* 1991;161:383–8.
104. Aldridge M, Gruffaz F, Castaing D, et al. Adenomyomatosis of the gallbladder: a premalignant lesion? *Surgery* 1991;109:107–10. PMID: 1984629.